www.idakochi.org

JIDAK

Jul.- Sep. 2020, Volume 2 , Issue 3

JOURNAL OF INDIAN DENTAL ASSOCIATION - KOCHI

www.idakochi.org

JIDAK

Jul.- Sep. 2020, Volume 2 , Issue 3

JOURNAL OF INDIAN DENTAL ASSOCIATION - KOCHI

Journal of Indian Association of Kochi Branch (JIDAK) is the official scientific publication of Indian Dental Association, Kochi Branch. It is a peer-reviewed journal published quarterly in e-format as well as print format.

The journal invites manuscripts from dental and other allied health sciences. It publishes manuscripts under categories of Original Research, Review and Case Reports.

For submission of manuscripts,
log on to www.jidakochi.org.
For communications,
mail to jidakochi@gmail.com.

Chief Editors Message

Greetings from Team JIDAK

It is with immense pride and pleasure we are launching yet another issue of JIDAK, the academic spearhead of IDA Kochi !!

This issue of JIDAK which coincides with the auspicious 'Vijayadashami' and 'Vidyarambam' makes it even more special and we pray that it helps in sharing and spreading knowledge to all around us in this difficult times of the pandemic!

I would like to thank my entire team and the IDA KOCHI office for the continuous support in helping me take the JIDAK to greater heights of academic excellence !!

Seeking everyone's blessings and support..

Jai JIDAK

Jai IDA

Dr. Meera Gopalakrishnan
Chief Editor- JIDAK
IDA Kochi

CONTENTS

REVIEW ARTICLE

BOT GUIDED PROSTHODONTICS : A REVIEW

Author:

[1]Dr. Divya Mehta
[2]Dr. Prashant S Patil
[3]Dr. Ruchi Jain
[4]Dr. Surabhi Somkuwar

[1]Post Graduate Student
Department of Prosthodontics
Bhabha College of Dental Sciences
Bhopal, Madhya Pradesh, 462026

[2]Professor and Head
Department of Prosthodontics
Bhabha College of Dental Sciences
Bhopal, Madhya Pradesh, 462026

[3]Reader
Department of Prosthodontics
Bhabha College of Dental Sciences
Bhopal, Madhya Pradesh, 462026

[4]Senior Lecturer
Department of Prosthodontics
Bhabha College of Dental Sciences
Bhopal, Madhya Pradesh, 462026

Address for correspondence
Dr. Divya Mehta
Post Graduate Student
Department of Prosthodontics
Bhabha College of Dental Sciences
Bhopal, Madhya Pradesh, 462026
E mail: divrajjag@gmail.com

ABSTRACT

Application of robots for reducing the manual effort and increasing the accuracy of procedures are gaining momentum in various medical fields including dentistry. This article reviews the applications and progress thus far of the use of robots in prosthodontics. Robotic interventions in prosthodontics are mainly for designing and manufacturing of complete dentures and for assisting in dental implantology surgical procedures. In both cases, great progress has been achieved, helping to obtain higher level of accuracy in the procedures with high success rates. The time required tocomplete each procedure are considerably reduced with the use of robots. But such sophisticated and specially made robots for various prosthodontic treatments have to be used under the strict supervision of an expert dentist. There's no substitute for expert skill and clinical judgment.

Keywords: robots, dental implants, implant surgery, complete denture, tooth preparation.

J Ind Dent Assoc Kochi 2020;2(3):12-24.

INTRODUCTION

Robots are innovations by humans to attenuate manual efforts in hazardous working environments, to extend the accuracy and precision of the work being administered, and to attenuate manual labour. Robotics deals with the planning, development, operation, and use of robots, also as computer systems for his or her control, sensory feedback, and Inter disciplinary branch of engineering and science that has applied science, engineering science, computer science, and others. [1]

Various sorts of robots are already a part of our lifestyle, they support production in industrial applications, cut our grass and clean our floors.[2] The present generation of human-safe robots is finally ready to work directly with human co-workers, assist them and relieve them of tedious and laborious routine tasks.[3]

Robotic systems aren't intended as replacements for human doctors, but rather as smart surgical tools. They assist to extend the precision, quality and safety of surgical procedures.[1.]

In dentistry, Robotics remains in its infancy, although all the required technologies have already been developed and will easily be adapted. In prosthodontics, the appliance of robots is restricted mainly to the tooth arrangement in partial and complete dentures, tooth preparation in fixed partial dentures and in dental implantology. [4]

BACKGROUND ON DEVELOPMENTS IN ROBOTICS

Robotic systems aren't intended as replacements for human doctors, but rather as smart surgical tools. They help to increase the precision, quality and safety of surgical procedures. Their most valuable function may be their capacity to create an information link from pre-operative surgical plans to the surgical arena (Chart 1). [1]

HUMAN–ROBOT INTERACTION

The understanding, designing, and evaluation of robotic systems for use by or with humans is

CHART: 1 BACKGROUND ON DEVELOPMENTS IN ROBOTICS

In 1985, Programmable Universal Manipulation Arm (PUMA 560) robotic system was used in a neurosurgical biopsy.5

↓

In 1988, the same PUMA system was used to perform a robotic surgery - transurethral resection.5

↓

In 1994, the Automated Endoscopic System for Optimal Positioning (AESOP) robotic system became the first system approved by the Food and Drug Administration (FDA) for its endoscopic surgical procedure. AESOP was designed to manoeuvre an endoscope inside the patient's body during the surgery. The camera moves based on voice commands of the surgeon or through computer commands. 6

↓

In 1994, ZEUS surgical system was a successor of AESOP system, designed to assist in the control of blunt dissectors, retractors, graspers, and stabilizers during laparoscopic and thoracoscopy surgeries. 7,8

↓

The Da Vinchi Surgical (DVS) system, which was approved by FDA in 2000. 9,10 This system was designed to facilitate complex surgery using a minimally invasive approach, and is controlled by a surgeon from a console.

↓

The DVS system is currently used for a variety of surgical interventions: general, thoracic, cardiac, colorectal, gynaecology, urological, etc. 8

referred to as human-robot interaction. There are various modes of interaction between humans and robots.[11]

Physical human-robot interaction (PHRI)[12] has become increasingly relevant in modern robotics and will also play an important role in Dentronics applications. A former review article found haptics to be one of the key elements for robotics in dentistry.[13] Safe phri requires collaborative and sensitive robots and suitable compliant behaviour made possible by appropriate controllers.[14] An example for physical communication between humans and robots are haptic gestures. They allow the human to relay context-dependent intentions to the robot by touching it.[15] In a broader context, button interfaces are also related to physical interaction, especially if they are mounted on the robot in order to form an integrated direct control as for example on the Franka Emika Panda arm or the Baxter platform.[16]

Another rather basic form of contact-based interaction are graphical interfaces such as where it is important to not overwhelm the user with information but focus on the current context. However, these methods may not be as intuitive as direct physical interaction with the robot.[17]

Contact-free interaction modalities like visual interaction based on RGB-D camera systems or similar technologies such as infrared have been researched for many years. Especially, in dental scenarios this would be a great benefit as the dentist most of the time cannot move around freely to interact with a robot directly. In order to establish such type of communication, visually recognizable gestures like waving, hand opening/closing or pointing are utilized.[18,19] Visual communication is under the assumption that the dentist can move hands but cannot move around to directly touch the robot and after short auditory/visual cues for commands the dentist has hands free while the robot does its work autonomously. Furthermore, voice recognition and foot-pedal controlled commands are possible.[20]

More advanced techniques involve motion tracking of humans or face recognition. Its advantages are that no direct contact with the robot is necessary and a certain degree of comfort for the human user is created since they do not have to alter their respective location. Despite major advantages over the last years, the systems are still sensitive to factors such as different lighting, obstacles and still require substantial computational resources.[21]

Auditory interaction includes verbal communication and general sound signals to relay information between humans and robots.[22] Simple sound signals are often employed to support other means of communication e.g. A confirmation sound when pressing buttons or performing a haptic gesture. Verbal communication requires much more advanced algorithms and still is prone to errors in practice. While text to speech (TTS) is comparatively widespread and easy to implement, general speech recognition is a difficult problem especially in a quite unstructured scenario such as a dental office. By leveraging large amounts of data, neural networks have proven to be a promising approach.[23]

PROGRAMMING & MACHINE LEARNING

Before the emergence of collaborative and soft robots in the last decade most platforms - required a tedious and time-consuming process in order to be programmed even for the simplest tasks. Today's technological level allows for much more intuitive and efficient programming schemes.[24]

The term machine learning (ML) summarizes different methods for making use of possibly large amounts of data to learn and self-improve from own experience.[25]

Kinesthetic Teaching (KT) & Teleoperation (TO) are 2 methods for machine learning (Figure 1). In KT, the teacher physically manoeuvres the robot (Figure 2) while in TO it is performed with the help of Sensable's Phantom Omni R which

Fig. 1 : Types of programming

Fig.2: Kinesthetic teaching



Fig.3: Teleoperation

is a haptic device having 6-degree of freedom positional sensing (Figure 3).[26]

CONTROL OF A ROBOT

The controller of a robot determines how its joints are actuated depending on sensory input and is therefore directly related to the way it is explicitly or implicitly interacting with the environment. The application of robotic systems in a dental scenario requires the capability of sensitive physical interaction without causing any form of harm to the environment or the system itself. In robotics, impedance control[27] became an essential framework that still serves as the basis for many modern control systems fulfilling this requirement. It enables robots to safely interact with the environment in a similar manner as humans do by mimicking the compliant human motor control behaviour. This stands in vast contrast to classical position-controlled industrial robots used at assembly lines and in segregated workspaces from humans.[28]

ARTIFICIAL INTELLIGENCE

In the context of robotics, the field of autonomous task planning comprises methods from classical artificial intelligence such as tree-search algorithms and symbolic task planning that are used to autonomously plan a sequence of actions in order to achieve a desired goal. Most of these methods originate from works that are unrelated to robotics yet very much applicable.[29] Generally, autonomous robots depend on a knowledge base in order to reliably perform their assigned tasks. Examples for stored knowledge are taxonomies of skills, i.e. The capabilities of the robot, 3D-maps of the surroundings or general information about the robot. Furthermore, they have to be able to reason about current events and new information in order to adapt to new situations.[30,31]

SAFETY

Human safety is among the most important aspects in a human-robot co-working scenario. Especially in the last decade there has been extensive research about this topic in order to determine requirements of safe robots and studies regarding injuries which resulted in the development of novel design paradigms that aim to make modern robots inherently safe.[32]

In particular, some works address safety issues and led to new safety standards such as ISO 13482-3 (safety of machinery - functional safety of safety-related electrical, electronic and programmable electronic control systems).[14] Within the soft robotics paradigm joint torque sensors with suitable disturbance observers are used for human-robot contact handling and, more general, for unified collision handling and reflex reaction.[33]

To prevent injuries of human co-workers in unintended collisions, safe motion control methods were developed[34], determining the maximum allowed velocity for ensuring human safety by means of an injury database and the current robot configuration, an essen-

tial component to let humans and robots share physical spaces and seamlessly interact.[35]

Beyond considering the isolated robot alone also its workplace in its entirety shall be considered when designing a safe work environment.[36] Within the European Economic Area, a robot system has to be provided with a CE marking which confirms the safety, health and environmental protection standards for products.[37]

ROBOTICS IN DENTISTRY

MAXILLOFACIAL SURGERY

Applications of digitalization in maxillofacial surgery with a special emphasis on the combination of implant dentistry and prosthodontics or on the positive effects of robot-assisted surgery in head and neck cancer.

The development of computer-assisted implant surgery based on the concept of prosthetic-driven implantology and CT-scan analysis have been reviewed. Although advances in technological readiness have been made, issues such as high costs and inherent complexity of the techniques and hardware utilized are still to be overcome.[38]

Orthognathic surgery was performed in a preliminary experiment with a jawbone skull phantom. However, Woo et al. Found that before automated orthognathic surgery can be tested in human studies the available software needs to be optimized and safety of the hardware augmented.[39]

A pilot phantom study concluded that implant placement with a six-axis robotic arm can improve accuracy of the operation in zygomatic implant placement. A surgical robotic application which has made it to reality is an invasive robotic assistant for dental implantology. It was permitted for operative use by the FDA (Food and Drug Administration) in March 2017.[40]

Human-related factors (such as reduced concentration, trembling, distraction or reduced vision) affect the accuracy and safety in maxillofacial surgery. A study proposed an autonomous surgical system aiming to conduct maxillofacial surgeries under the assistance and surveillance of the surgeon. A navigation module and a robot were seamlessly integrated into this system and a drilling experiment was conducted on five 3D printed mandible models to test the pose detecting capability and evaluate the operational performance. The experiment showed that this system was able to successfully guide the robot finishing the operation regardless of the mandible position.[41]

ROOT CANAL TREATMENT AND PLAQUE REMOVAL

Root canal treatment is a procedure which is based on high accuracy. Usually, a dentist specialized in endodontics works using magnification to assure adequate view of the root canal. Nelson et al. Published the idea of a robotic system for assistance during root canal treatment. The so-called "vending machine" was supposed to supply the dentist with the necessary root canal instruments during treatment in order to reduce deflection from the operating site. A recent study proposed the application of micro-robots with catalytic-ability to destroy biofilms within the root canal and tested the system In vitro. Furthermore, the authors discussed the use of these systems for other applications such as prevention of tooth decay or peri-implant infection.[42,43]

ORTHODONTICS AND JAW MOVEMENT

A novel system that generates the dental arch form has been developed. The system can be used to bend orthodontic wires.[44] Edinger described a robot for the dental office for the first time in 1991, later he described a robotic system to reproduce condylar movements.[45,46] Virtual articulators are one of the technological bases necessary to fully rethink and digitalize dental workflows. They enable simulation of occlusal changes in the digital world and may be strongly empowered by AI in the future to e.g. Simulate use of dental materials patient-individually or simulate treatment outcomes of implant placement or maxilla-facial surgeries.[47]

X-RAY IMAGING RADIOGRAPHY

Positioning of the film/sensor and the X-ray source was proposed to be executed by a 6 dof

robotic arm and was found to have no adverse effects. Results showed that the robotic system was superior to the mechanical alignment approach, due to its excellent accuracy and repeatability.[48,49] Another application presented in the literature is a robot equipped with a skull to investigate the influence of head movement to the accuracy of 3D imaging.[50]

MATERIAL TESTING

Robotic dental wear and mastication simulators are proposed to test tooth filling materials[51] or dental implant materials.[52] One of the systems was driven by a robot with 6 dof robotic arm.[53] In another study dental impression materials were tested with the help of a robotic arm.[54]

TESTING OF TOOTHBRUSHES

The efficiency of toothbrushes and their abrasiveness towards enamel may be tested with highest repeatability and comparability by using robotic systems. For example, an in vitro study with a six-axis robot compared the efficiency of two different tooth brushes with clinical hand brushing and in vitro robotic brushing. Results showed that robotic brushing of teeth is an alternative for plaque removal studies and may even replace clinical studies.[55]

ROBOT ASSISTANT

The possibility of active robotic support during treatments by handling of instruments via a multi-modal communication framework that aims at dentists as users. It comprises of bilateral physical human–robot interaction, touch display input, speech input and visual gestures. In their approach they used a state of-the-art safe collaborative and sensitive 7dof robot and conducted a user-study to explore the feasibility of different human-robot interaction modalities in dentistry.[56]

ROBOTIC EDUCATION

The idea of a dental training robot was first described in 1969.[57] The application of a humanoid in dental education was tested in 2017. A humanoid, a full-body patient simulation system (SIMROID), was tested during a study among dental students to seek out whether a robotic patient was more realistic for the scholars to familiarize with real patients[58] than the usually used dummies. “Hanako”, the SIMROID is standing 165 cm tall. It comes with a metal skeleton and vinyl chloride-based gum pattern of skin. “Hanako” is a stimulating contribution to education in dentistry because the SIMROID is imitating a person's in its actions and expressions. It can verbally express pain, roll its eyes, blink, shake its head in pain, perform movements of jaw, tongue, elbow and wrist. Furthermore, it can even simulate a vomiting reflex with a uvula sensor, and also simulate functions to induce bleeding and saliva flow.[59]

Tanzawa et al. Introduced a medical emergency robot with the aim to assist dental students to urge conversant in emergency situations.[60] Another robotic educational equipment described within the literature is that the ROBOTUTOR. This tool was developed as an alternate to a clinician to demonstrate tooth-cleaning techniques to patients. It's a robotic device to coach and show brushing techniques. Additionally, a study investigated the training experience of pre-clinical dental students using 3D printed teeth designed with realistic pulp cavities and simulated caries decays.[61]

ROBOTICS IN PROSTHODONTICS

TOOTH ARRANGEMENT FOR COMPLETE DENTURES

The traditional way of complete denture manufacturing is manual, and therefore the key step of the procedure is to implant artificial teeth into a tooth pad in their correct positions and orientations. Only speciality dentists and skilled technicians can do that work well. This traditional approach is now replaced with the utilization of robots to manufacture denture systems. Complete dentures vary considerably in tooth size, the relative position and orientation of every tooth, and therefore the shape of the teeth arch curve. The advantage of a robot is

Fig.4:
Robotic arm of the typical CRS robot system

its operational flexibility, and may be adapted for handling the manufacture of complete dentures.[62,63]

CRS Robotics Corporation (Figure 4), Canada, produced one manipulator robotic system with 6 dofs. This technique was then adapted for the manufacture of complete dentures. The most components of the system[64] are: (1) CRS robot, (2) electromagnetic gripper, (3) a computer, (4) a central system with tooth-arrangement and robot control software for tooth-arrangement, motion planning and control, (5) denture base, (6) light device, and (7) light-sensitive glue.

The three-dimensional virtual tooth-arrangement software of the robotic system helps to make medical record files of a patient, draw a jaw arch and dental arch curves by expert's experience consistent with the jaw arch parameters of the patient, and adjust the dental arch curve. It then displays the three-dimensional virtual dentitions on the screen, provide a virtual observation environment for designed dentitions, and interactively modify each tooth posture. The calibration of the tooth arrangement, initial positioning of the robot, creating control data for tooth arrangement and therefore the overall control of the robot is done by the robot control software. The utmost loads this robot system can handle is 3 Kg, the utmost line velocity is 4.35 m/s, and therefore the repeated positioning accuracy is ±0.05 mm. This technique was then adapted for the manufacture of an entire denture system for patients. The system relies on the utilization of a special light sensitive material that hardens under lighting. During this system, a robot grasps selected standard teeth and implants them in fixed positions. However, it had been found that the system had difficulty in grasping and manipulating the synthetic teeth accurately. This led to the event of more improved robotic systems with more number of dofs.[65]

Further research led to the planning of a complicated 84 DOF system with 14 independent tooth manipulators on the dental arch curve. So as to regulate the tooth's position on the dental arch, the manipulators were designed to maneuverer along its tail in both directions. There was a tooth arrangement helper within the system with 6 dofs (three rotations and three movements) to regulate the tooth for its position along X, Y, Z, lingual, rotation and near-far-medium directions. This robotic system is in a position to understand any posture within the artificial teeth space, and solved many problems of the only robotic system. But one major disadvantage of this technique is that it's driven by [84] independent motors and hence difficult to regulate it which reduced the efficiency. A way improved 50 DOF tooth arrangement robotic system was then designed with 14 independent manipulators, a dental arch generator and a slipway mechanism as its components.[66] Dental arch generator creates the dental arch curve and matches with the one from the patient's mouth. The slipway mechanism is employed to regulate the dental arch generator. As within the 84 DOF robotic system, the 14 independent manipulators are ready to move along its own tail to regulate for every tooth's rotation. Each of those manipulators had 3 dofs (two rotations and one movement) to regulate each tooth for its position along Z, lingual and near-far-medium directions. The extra 3 dofs for adjusting the tooth within the X, Y and rotation are achieved by two parallel and rotatable vertical bars placed under every single manipulator. This type of adjustment helped to decrease the amount of motors required to drive the system to 50, thus increasing the efficiency of the system. Compared to previous generation systems, this 50 DOF tooth arrangement robotic system is straightforward and straightforward to regulate and takes only

half-hour for the manufacture of an entire denture. The repeated positioning accuracy of the system is ± 0.07 mm for single manipulator and ±0.1 mm for the entire robotic system. Though there are tremendous progress in improving the efficiency of the entire denture manufacturing robotic system, the procedure still remains mostly a manual operation. The high cost and lack of operational knowledge of the system are the most hindrance for the wide spread use of the system.[67]

TOOTH PREPARATION

Preparation of a tooth for crowns and bridges is a routine task for the dentist, although even after years of practical experience it is still challenging. The challenge is to reduce the tooth sufficiently to create space for the prosthetic rehabilitation with a minimum of damage to sound tooth structure. The idea of a robotic arm used for tooth preparation or preparation support for the dentist seems tempting and sensible. A mechatronic system to support the dentist in drilling has been tested in vitro and showed good results, however, it has not yet been validated in a clinical setting. The dentist 's position accuracy was 53% better with the mechatronic system than without it.[68] Yuan et al. Described a robotic tooth preparation system[69] with the following hardware components: (1) an intraoral 3D scanner to obtain the 3D data of the patient's target tooth, adjacent teeth, opposing teeth and the teeth fixture; (2) a computer-aided design (CAD)/computer-aided manufacturing (CAM) software for designing the target preparation shape and generating a 3D motion path of the laser; (3) an effective low-heat laser suitable for hard tissue preparation; (4) a 6 dof robot arm; (5) a tooth fixture connecting the robotic device with the target tooth and protecting the adjacent teeth from laser cutting, designed using Solid works software. Moreover, other tooth preparation devices were tested for their accuracy. A system with micro robots, controlling a picosecond laser showed a preparation accuracy that met clinical needs, the error was about (0.089 ± 0.026)mm.[70,71] Another tooth preparation system for veneers with a rotating diamond instrument mounted on a robotic arm was compared to human hand crown preparation & showed better results than the tooth preparation carried out by the dentist.[73]

DENTAL IMPLANTOLOGY ROBOT

Applications of computer assisted preoperative procedures like CAD/CAM are followed in dental implantology for long. But the utilization of robots for the surgery is comparatively new. Applications of robots for the implant surgery was a search theme in many of the research and medical centres over the recent period. They're considered as a breakthrough in utilizing the applications of computer assisted pre- surgical getting to the usage of robots within the surgical phase.[74]

The general features of those systems were a robotic arm with drilling tools, a knowledge acquisition board, strain gauges for stress/strain evaluation, and a force/torque sensor (equipped with accelerometers) placed on the robot wrist.[13] This technique can realize drilling and implant insertion. The robot is programmed to perform the implant drilling operation with the assistance of a dental drilling tool and also to use pressure on the assembled implants to simulate the mastication process. The system software consists of robot calibration module, drill plan module, load plan module, drill execution module, and acquisition data module. The optimal number of implants and their placement/orientation is studied through the implant force, and therefore the stress/strain analysis of jaw bone tissue with the various drilling posture.

Fig. 5
Yomi dental implantology robotic system

The first commercially available and state of the art robotic system for dental implantology, named as Yomi (Figure 5) was developed by Neocis Inc, USA and approved by FDA in 2017 (U.S. Food and Drug Administration, 2017). Yomi may be a computerized system intended to supply assistance in both the design (pre-operative) and therefore the surgical (intra-operative) phases of dental implantation surgery. The system provides software to preoperatively plan dental implantation procedures and provides navigational guidance of the surgical instruments. Yomi delivers physical guidance through the utilization of haptic robotic technology, which constrains the hammer in position, orientation, and depth. This assistive technology leaves the surgeon on top of things in the least times. Unlike plastic surgical guides, Yomi allows for clear visualization of the surgical site and enables the surgeon to dynamically change the plan.[75]

ADVANTAGES AND DISADVANTAGES

Dental robots have several advantages and disadvantages. They are:

ADVANTAGES

- Extremely high accuracy and precision.
- Stable and untiring, and hence can be used repeatedly without rest.
- Able to accurately process and judge quantitative information fed into the system.

DISADVANTAGES

- No judgment of the situation and hence unable to use any qualitative information.
- Continuous monitoring of an experienced dentist is always required.
- These devices still remain very expensive and out of reach of the common man.

CONCLUSION

Dentistry is moving forward towards a new era of data-driven and robot-assisted medicine. Robotic assistance in prosthodontic applications will remain an intensively discussed topic in the coming years. Tremendous progress has been achieved in the utilizing the positive aspects of robotics for various applications of dentistry. In prosthodontics, incorporation of robots is mainly in the design and manufacture of complete dentures, tooth preparation & in implantology. Use of sophisticated and specially made robots helps to improve the accuracy and precision of various prosthodontic treatments under the supervision of an expert dentist. But the human interventions cannot be completely ruled out. There's no substitute for expert skill and clinical judgment.

REFERENCES

1. Jon T. Lea, Dane Watkins, Aaron Mills, Micheal A. Peshkin, Thomas C Kienzle, S David Stulberg (1995) Registration and immobilization in robot-assisted surgery, Journal of Image Guided Surgery 1 (2), pp. 80 -87, 1995.
2. Haddadin S, Suppa M, Fuchs S, Bodenmüller T, Albu-Schäffer A, Hirzinger G. Konzeptefür den Roboterassistenten der Zukunft – towards the robotic co-worker. at – Automatisierungstechnik 2010; 58:695–708.
3. Chandrasekaran B, Conrad JM. Human–robot collaboration: a survey. SoutheastCon 2015; 2015:1–8.
4. Jin-gang Jiang, Yong-de Zhang, Chun-ge Wei, Tian-hua He, and Yi Liu (2014), A Review on Ronot in Prosthodontics and Orthodontics, Advances in Mechanical Engineering, Article ID 198748.
5. Anthony R. Lanfranco, Andres E. Castellanos, Jayadev P Desai and William C Mayers (2004), Annals of Survery, Robotic surgery: a current perspective, 239, pp. 14-21.
6. Unger SW, Unger HM, Bass RT (1994) AESOP robotic arm. SurgEndosc 8:1131.
7. Satava RM (2003) Robotic surgery: from past to future: a personal journey. Surg Clin North Am 83:1491–1500.
8. Tiago Leal Ghezzi and OlyCorleta (2016),

30 years of robotic surgery, World Journal of Surgery, 2016,

9. Himpens J, Leman G, Cadiere GB (1998) Telesurgical laparoscopic cholecystectomy. SurgEndosc 12(8):1091.

10. Hagen ME, Stein H, Curet MJ (2014) Introduction to the robotic system. In: Kim CH (ed) Robotics in general surgery. Springer, New York, pp 9–16.

11. Michael AG, Alan CS. Human-robot interaction: a survey. Now Foundations and Trends; 2008.

12. De Santis A, Siciliano B, De Luca A, Bicchi A. An atlas of physical human–robot interaction. Mech Mach Theory 2008; 43:253–70.

13. Kapoor S, Arora P, Kapoor V, Jayachandran M, Tiwari M. Haptics – touch feedback technology widening the horizon of medicine. J Clin Diagn Res 2014; 8:294–9.

14. Haddadin S. Towards safe robots. Berlin/Heidelberg: Springer; 2014

15. Argall BD, Billard AG. A survey of tactile human–robot interactions. Robot AutonSyst 2010; 58:1159–76.

16. Fitzgerald C. Developing baxter. 2013 IEEE conference on technologies for practical robot applications (TePRA) 2013:1–6.

17. Daniel B, Korondi P, Sziebig G, Thomessen T. Evaluation of flexible graphical user interface for intuitive human robot interactions. Acta Polytech Hung 2014; 11:135–51.

18. Ende T, Haddadin S, Parusel S, Wüsthoff T, Hassenzahl M, Albu-Schäffer A. A human-centered approach to robot gesture based communication within collaborative working processes. 2011 IEEE/RSJ international conference on intelligent robots and systems 2011:3367–74.

19. Gleeson B, Maclean K, Haddadi A, Croft E, Alcazar J. Gestures for industry intuitive human–robot communication from human observation; 2013.

20. Rautaray SS, Agrawal A. Vision based hand gesture recognition for human computer interaction: a survey. ArtifIntell Rev 2015; 43:1–54.

21. Li SZ, Jain AK. Handbook of face recognition. Springer Publishing Company, Incorporated; 2011.

22. Stiefelhagen R, Fugen C, Gieselmann R, Holzapfel H, Nickel K, Waibel A. Natural human–robot interaction using speech, head pose and gestures. 2004 IEEE/RSJ international conference on intelligent robots and systems (IROS) (IEEE Cat No. 04CH37566), vol. 3 2004:2422–7.

23. Graves A, Mohamed A, Hinton G. Speech recognition with deep recurrent neural networks. 2013 IEEE international conference on acoustics, speech and signal processing 2013:6645–9.

24. Safeea M, Neto P. KUKA sunrise toolbox: interfacing collaborative robots with MATLAB. IEEE Robot Autom Magazine 2019; 26:91–6.

25. Weiss K, Khoshgoftaar TM, Wang D. A survey of transfer learning. J Big Data 2016; 3:9.

26. B. Argall, S. Chernova, M. M. Veloso, and B. Browning. A survey of robot learning from demonstration. Robotics and Autonomous Systems, 57(5):469–483, 2009.

27. Hogan N. Impedance control: an approach to manipulation: Part II. Implementation. J DynamSystMeas Control 1985; 107:8.

28. Khatib O. A unified approach for motion and force control of robot manipulators: the operational space formulation. IEEE J Robot Autom 1987; 3:43–53.

29. Russell S, Norvig P. Artificial intelligence: a modern approach. Global Edition Pearson Education Limited; 2016.

30. Erdem E, Aker E, Patoglu V. Answer set programming for collaborative housekeeping robotics: representation, reasoning, and execution. IntellServ Robot 2012;5: 275–91.

31. Tenorth M, Beetz M. Representations for

robot knowledge in the KnowRob framework. ArtifIntell 2017;247: 151–69.

32. Haddadin S, Albu-Schäeffer A, Hirzinger G. Requirements for safe robots: measurements, analysis and new insights. Int J Robot Res 2009; 28:11–2.

33. Johannsmeier L, Haddadin S. A hierarchical human–robot interaction-planning framework for task allocation in collaborative industrial assembly processes. IEEE Robot Autom Lett 2017; 2:41–8.

34. Haddadin S, Haddadin S, Khoury A, Rokahr T, Parusel S, Burgkart R, et al. On making robots understand safety: embedding injury knowledge into control. Int J Rob Res 2012; 31:1578–602.

35. Mansfeld N, Hamad M, Becker M, Marin AG, Haddadin S. Safety map: a unified representation for biomechanics impact data and robot instantaneous dynamic properties. IEEE Robot Autom Lett 2018; 3:1880–7.

36. Michalos G, Makris S, Tsarouchi P, Guasch T, Kontovrakis D, Chryssolouris G. Design considerations for safe human–robot collaborative workplaces. Proc. CIRP 2015; 37:248–53.

37. Guide to application of the Machinery Directive 2006/42/EC. 2.1 ed. European Commission; 2017.

38. Hassfeld S, Brief J, Raczkowsky J, Marmulla R, Mende U, Ziegler C. Computer-based approaches for maxillofacial interventions. Minim InvasTher Allied Technol 2003; 12:25–35.

39. Woo S-Y, Lee S-J, Yoo J-Y, Han J-J, Hwang S-J, Huh K-H, et al. Autonomous bone reposition around anatomical landmark for robot-assisted orthognathic surgery. J Cranio-MaxillofacSurg 2017; 45:1980–8.

40. Sun X, McKenzie FD, Bawab S, Li J, Yoon Y, Huang JK. Automated dental implantation using image-guided robotics: registration results. Int J Comput Assist RadiolSurg 2011; 6:627–34.

41. Ma Q, Kobayashi E, Wang J, Hara K, Suenaga H, Sakuma I, et al. Development and preliminary evaluation of an autonomous surgical system for oral and maxillofacial surgery. Int J Med Robot 2019;15: e1997.

42. Nelson CA, Hossain SG, Al-Okaily A, Ong J. A novel vending machine for supplying root canal tools during surgery. J Med EngTechnol 2012; 36:102–16.

43. Hwang G, Paula A, Hunter E, Liu Y, Babeer A, Karabucak B, et al. Catalytic antimicrobial robots for biofilm eradication. Sci Robot 2019;4: eaaw2388.

44. Jiang JG, Zhang YD. Motion planning and synchronized control of the dental arch generator of the tooth-arrangement robot. Int J Med Robot 2013; 9:94–102.

45. Edinger D. Robot system for the dental office. Phillip J 1991; 8:301–2, 5–6, 8.

46. Edinger DH. Accuracy of a robotic system for the reproduction of condylar movements: a preliminary report. Quintessence Int 2004; 35:519–23.

47. Lepidi L, Chen Z, Ravida A, Lan T, Wang HL, Li J. A full-digital technique to mount a maxillary arch scan on a virtual articulator. J Prosthodont 2019; 28:335–8.

48. Burdea GC, Dunn SM, Levy G. Evaluation of robot-based registration for subtraction radiography. Med Image Anal 1999; 3:265–74.

49. Burdea GC, Dunn SM, Immendorf CH, Mallik M. Real-time sensing of tooth position for dental digital subtraction radiography. IEEE Trans Biomed Eng 1991; 38:366–78.

50. Spin-Neto R, Mudrak J, Matzen LH, Christensen J, Gotfredsen E, Wenzel A. Cone beam CT image artefacts related to head motion simulated by a robot skull: visual characteristics and impact on image quality. DentomaxillofacRadiol 2013; 42:32310645.

51. Conserva E, Menini M, Tealdo T, Bevilacqua M, Pera F, Ravera G, et al. Robotic chewing

simulator for dental materials testing on a sensor-equipped implant setup. Int J Prosthodont 2008; 21:501–8.

52. Tahir AM, Jilich M, Trinh DC, Cannata G, Barberis F, Zoppi M. Architecture and design of a robotic mastication simulator for interactive load testing of dental implants and the mandible. J Prosthet Dent 2019;122, 389.e1–389.e8.

53. Raabe D, Alemzadeh K, Harrison AL, Ireland AJ. The chewing robot: a new biologically-inspired way to evaluate dental restorative materials. Conf Proc IEEE Eng Med Biol Soc 2009:6050–3.

54. Carvalho A, Brito P, Santos J, Caramelo FJ, Veiga G, Vasconcelos B, et al. Evaluation of two dental impression materials using a robot arm. Bull Group Int Rech Sci StomatolOdontol 2011; 50:36–7.

55. Lang T, Staufer S, Jennes B, Gaengler P. Clinical validation of robot simulation of toothbrushing-comparative plaque removal efficacy. BMC Oral Health 2014; 14:82.

56. Grischke J, Johannsmeier L, Eich L, Haddadin S. Dentronics: first concepts and pilot study of a new application domain for collaborative robots in dental assistance. In: 2019 international conference on robotics and automation (ICRA). 2019.

57. A dental training robot. J Kans State Dent Assoc 1969; 53:161.

58. Abe S, Noguchi N, Matsuka Y, Shinohara C, Kimura T, Oka K, et al. Educational effects using a robot patient simulation system for development of clinical attitude. Eur J Dent Educ 2018;22: e327–36.

59. Takanobu H, Okino A, Takanishi A, Madokoro M, Miyazaki Y, Maki K. Dental patient robot. 2006 IEEE/RSJ international conference on intelligent robots and systems 2006:1273–8.

60. Tanzawa T, Futaki K, Kurabayashi H, Goto K, Yoshihama Y, Hasegawa T, et al. Medical emergency education using a robot patient in a dental setting. Eur J Dent Educ 2013;17: e114–9.

61. Höhne C, Schmitter M. 3D printed teeth for the preclinical education of dental students. J Dent Educ 2019; 83:1100–6.

62. Y. D. Zhang, Z. F. Zhao, J. L. Lu, and S. K Tso, (2001) Robotic manufacturing of complete dentures, Proceedings of the IEEE International Conference on Robotics and Automation, pp. 2261– 2266, Piscataway, NJ, USA, 2001

63. R.-J. Song, -D hang, -F hao, - u, and Wang, (2001), A tooth arrangement algorithm for robot aided denture processing," ournal of Beijing Institute of Technology, vol. 21, no. 4, pp. 474–479.

64. P. Lu, Y. Wang, and G. Li, (2001) Development of a system for robot aided teeth alignment of complete denture," Chinese journal of stomatology, vol. 36, no. 2, pp. 139–142.

65. Y. Zhang, J. Ma, Y. Zhao, L. Peijun, and Y. Wang (2008) Kinematic analysis of tooth-arrangement robot with serial-parallel joints, Proceedings of the IEEE International Conference on Information and Automation (ICIA '08), pp 624–628, Hunan, China.

66. Y.-D. Zhang, J.-G. Jiang, P.-J. Lv, and Y. Wang (2011) Study on the multi-manipulator tooth-arrangement robot for complete denture manufacturing, Industrial Robot, vol. 38, no. 1, pp. 20– 26.

67. Y.-D. Zhang, J.-G. Jiang, P.-J. Lv, and Y. Wang (2010) Coordinated control and experimentation of the dental arch generator of the tooth-arrangement robot, The International Journal of Medical Robotics and Computer Assisted Surgery, vol. 6, no. 4, pp. 473– 482.

68. Ortiz Simon JL, Martinez AM, Espinoza DL, Romero Velazquez JG. Mechatronic assistant system for dental drill handling. Int J Med Robot 2011; 7:22–6.

69. Wang D, Wang L, Zhang Y, Lv P, Sun Y, Xiao J. Preliminary study on a miniature laser

manipulation robotic device for tooth crown preparation. Int J Med Robot 2014;10: 482–94.

70. Yuan FS, Wang Y, Zhang YP, Sun YC, Wang DX, Lyu PJ. Study on the appropriate parameters of automatic full crown tooth preparation for dental tooth preparation robot. Zhonghua Kou Qiang Yi Xue Za Zhi 2017; 52:270–3.

71. Yuan F, Wang Y, Zhang Y, Sun Y, Wang D, Lyu P. An automatic tooth preparation technique: a preliminary study. Sci Rep 2016; 6:25281.

72. Otani T, Raigrodski A, Mancl L, Kanuma I, Rosen J. In vitro evaluation of accuracy and precision of automated robotic tooth preparation system for porcelain laminate veneers. J Prosthetic Dent 2015:114.

73. Y.-D. Zhang, J.-G. Jiang, and T. Liang (2011) Structural design of a cartesian coordinate tooth-arrangement robot, Proceedings of the International Conference on Electronic and Mechanical Engineering and Information Technology (EMEIT '11), pp 1099– 1102, Harbin, China.

74. J. N. Pires, F. J. Caramelo, P. Brito, J. Santos, and M. F. Botelho (2006) Robotics in implant dentistry: stress/strain analysis System overview and experiments," Industrial Robot, vol. 33, no. 5, pp. 373–380.

75. U.S. Food and Drug Administration, Department of Health and Human Services. Approval letter, December 22, 2016.

GINGIVAL DEPIGMENTATION - GROWING TREND IN COSMETIC DENTISTRY

Authors:

Dr. Reshma Menon[1]
Dr. MajoAmbooken[2]
Dr. Jayan Jacob Mathew[3]
Dr.Priya John[4]

Post Graduate Student[1]
Department of Periodontics
Mar Baselios Dental College
Kothamangalam, Kerala

Professor and Head[2]
Department of Periodontics
Mar Baselios Dental College
Kothamangalam, Kerala

Professor[3]
Department of Periodontics
Mar Baselios Dental College
Kothamangalam, Kerala

Reader[4]
Department of Periodontics
Mar Baselios Dental College
Kothamangalam, Kerala

Address for correspondence
Dr.Reshma Menon
Post Graduate Student
Department of Periodontics
Mar Baselios Dental College
Kothamangalam, Kerala
E mail: reshmam24@gmail.com

ABSTRACT

Gingival hyperpigmentation or black gums has been considered as less attractive or unaesthetic by majority of population. Most of the people believe that their smile is more important to their appearance than hair and eyes. Gingival depigmentation refers to those periodontal plastic surgical procedures aimed at reducing or removing the hyperpigmentation. Review article here briefs out those treatment procedures.

Keywords: Depigmentation, Melanin, Laser, Scalpel.

J Ind Dent Assoc Kochi 2020;2(3):25-32.

INTRODUCTION

A genuine smile comes from the heart, but a healthy smile needs a good dental care. Aesthetics has always been of prime importance in our society. An aesthetic smile require a harmonious interrelationship of the pink with white. The soft tissue periodontal plastic procedures were not only done to enhance the dentofacial harmony. The domain of periodontics over the year has changed from being strictly a health service to one where smile enhancement has been brought to the forefront of treatment planning[1].

Melanin producing cells in our body are called melanocytes. The active melanocytes convert tyrosine to melanoprotein mediated by tyrosinase enzymes, which are primarily responsible for the gingival color. The color of gingiva also depends on other factors like the severity of melanogenesis and depth of epithelial and gingival vascularization. In the process of melanogenisis, melanin pigments gets accumulated in melanosomes and further gets transferred to prickle and basal cell layers[2].

Gingival colour is generally described as coral pink. Excessive deposition of melanin located in the basal and supra-basal cell layers of the epithelium will result in gingival hyper pigmentation. (Dummett, 1979)

Pigmentation can be either by physiological process such as degradation products of melanin, melanoid, carotene, oxyhemoglobin, reduced hemoglobin, bilirubin and iron[3] and/or due to pathological diseases, and conditions (fig 1). Furthermore, environmental risk factors such as tobacco smoking, ethnicity and age also influence the color of gingiva.[4]

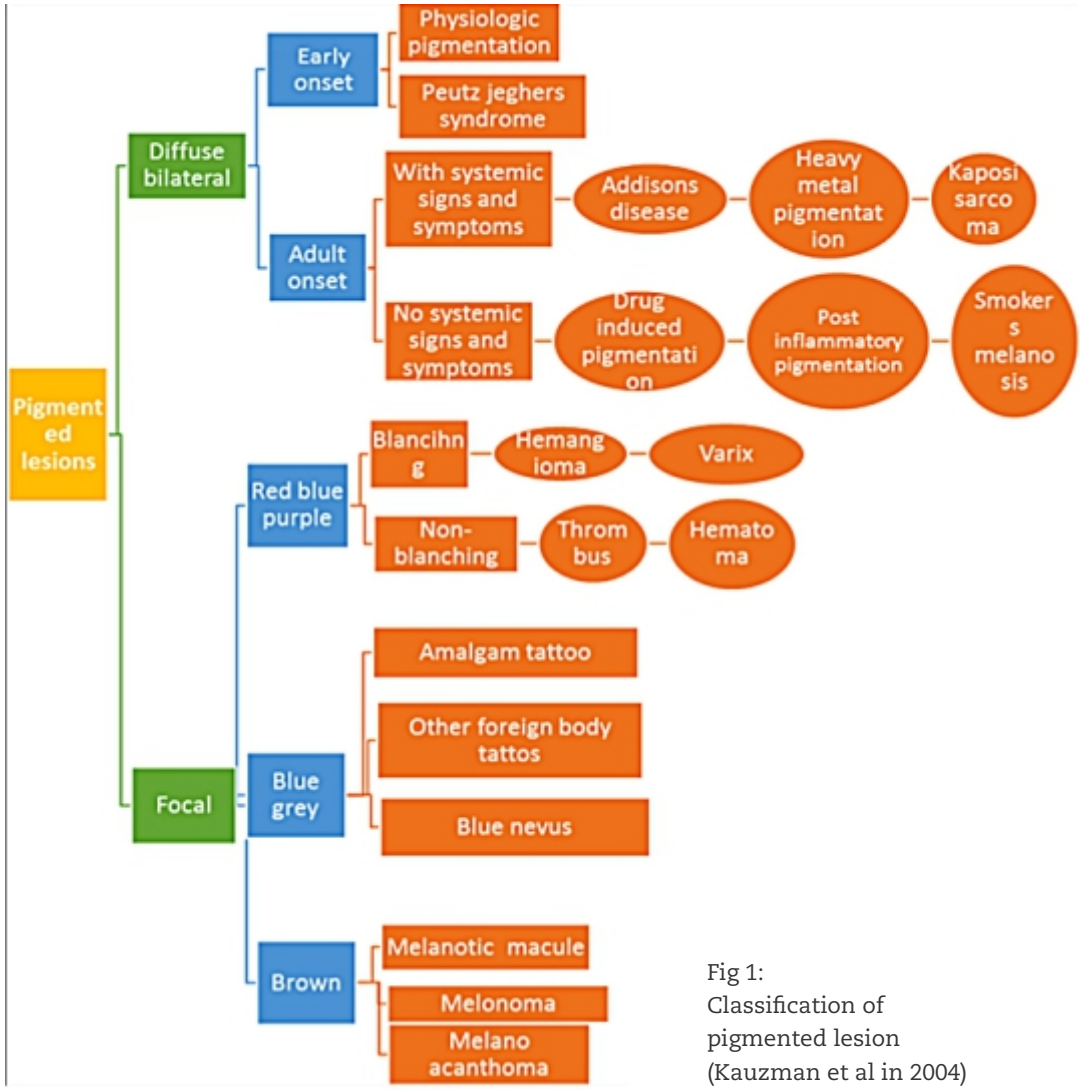

Fig 1:
Classification of pigmented lesion
(Kauzman et al in 2004)

Gingival hyper pigmentation is considered unaesthetic and unattractive by many people, especially those with high smile line and it brings down their confidence to smile. Many treatment modalities or gingival depigmentation procedures have been advocated for removal / reduction of pigmentation.

This review article briefs out various treatment approaches prevalent in dentistry for the management of gingival hyper pigmentation.

According to Roshni & Nandakumar[5]; different gingival depigmentation methods are:

A. Methods used to remove the gingival pigmentation:

1. SURGICAL METHODS:

- Scalpel surgical technique
- Bur abrasion method
- Electro-surgery
- Cryosurgery
- Lasers
- Radiosurgery

2. CHEMICAL METHODS

B. Methods used to mask the gingival pigmentation:

- Free gingival graft.
- Acellular dermal matrix allograft.

The selection of the appropriate depigmentation technique ought to be based on the type of presenting pigment, gingival biotype, clinical experience, patient's financial status and individual preferences[6].

SCALPEL SURGICAL TECHNIQUE

One of the very first and most commonly practiced technique is the surgical removal of undesirable pigmentation using scalpels. In this technique, the pigmented gingival epithelium along with a layer of the underlying connective tissue is surgically removed by splitting the epithelium with blade allowing the denuded connective tissue to heal by secondary intention. Care should be taken not to leave any pigmented remnants over the denuded area[5].

Scalpel surgery causes bleeding during and after the procedure and it is necessary to cover the surgical site that is exposed, with periodontal dressing for 7 to 10 days. After 6 weeks the attached gingiva will regenerate with only a delicate scar. The newly formed gingiva is clinically non-pigmented[7].

BUR ABRASION METHOD

In this abrasion technique a large round diamond bur is used in a high speed hand piece with copius irrigation for depigmentation. The procedure requires 45 min to 1 hour for com-

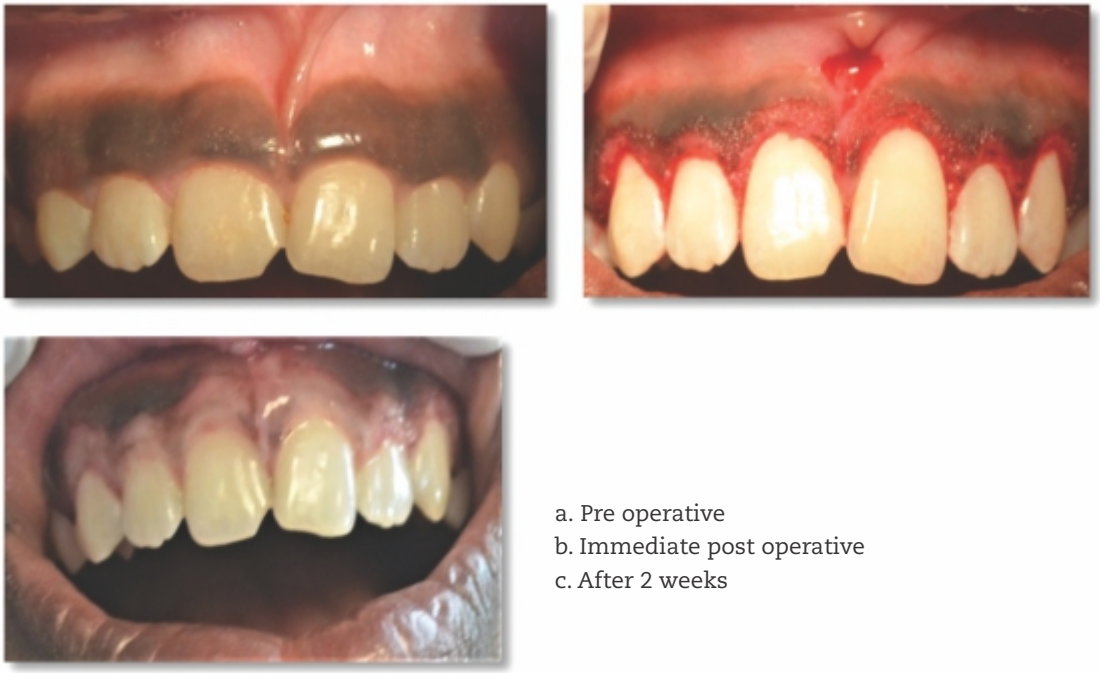

a. Pre operative
b. Immediate post operative
c. After 2 weeks

pletion. Pressure application should be minimal and feather light brushing strokes without holding the bur in one place is recommended. Extensive care is required to avoid over pitting of the gingival surface or removal of excessive tissue due to high speed[8].

Depending on the extent of the procedure, the denuded lamina propria of the depigmented areas may be covered by a surgical dressing for few days or by a surgical stent that matches the color of surrounding tissue[9].

It is relatively simple, safe, non-aggressive method and easy to perform, but difficulty remains in controlling the depth of de-epithelization and obtaining an adequate access.

Also depigmentation should be performed cautiously with the adjacent teeth well protected, since the inappropriate application can result in gingival recession, injury to underlying periosteum and bone, delayed wound healing, as well as enamel loss[10].

ELECTROSURGERY

According to Oringer's (1975) "exploding cell theory", it is predicted that the electrical energy leads to molecular disintegration of melanin cells present in basal and suprabasal cell layers of operated and surrounding sites. Electrosurgery works on this principal.

The diamond loop electrode fitted is mostly preferred. The tip of the electrode is swiftly moved over the pigmented tissue to be excised under local anasthesia. Electrode is used in a light brushing stroke and the tip is kept in motion all the time. The contact time of the tip of the electrode with the tissue should be very brief.

De-pigmentation by Electrocautery
Pic courtesy: Int J Oral Health Med Res 2017;3(6):36-39.

Keeping the tip in one place could lead to excessive heat buildup (Lateral heat accumulation) and destruction of the tissues[11].

After each use, the tip of the electrode is wiped on the rough surface of the saline-soaked gauze to remove all debris.

It takes lesser time and causes minimum bleeding, but when used for prolonged time it induces heat accumulation and causes undesired tissue destruction[12].

The surgical procedure is followed by immediate clot formation. The underlying tissue become acutely inflamed with some necrosis. This clot is then replaced by granulation tissue. After 24 hours there is increase in new connective tissue cells mainly angioblasts. By third day numerous young fibroblasts are found. The granulation tissue grows coronally creating a new marginal gingiva. Simultaneously after 12-24 hours epithelial cells at the margins start to migrate over the granulation tissues separating it from clot. Surface epithelialization is generally complete after 5-14 days[13].

LASERS

Commonly employed lasers for the procedure are

- Neodymium; aluminum-Yttrium-Garnet (Nd-YAG) laser
- Erbium-YAG lasers
- Carbon-di-oxide CO2 laser
- Diode lasers

All the suggested wavelengths are fast and effective in removing pigmentation and is well tolerated by patients. Esthetic results after laser therapy is often highly positive and satisfactory.

Diode lasers basically does not interact with dental hard tissues; it causes minimal damage to the periosteum and bone underlying the gingiva, and hence is an excellent soft tissue surgical laser. It exhibits thermal effects using the "hot-tip" effect caused by heat accumulation at the end of the fibre and produces a relatively thick coagulation layer on the treated surface.[14] The protein coagulum formed on the wound surface as a result of irradiation might act as a biologic wound dressing sealing the ends of sensory nerve endings.

a. Pre opertaive view b. Immediate post operative c. After 2 weeks

According to findings the duration of the procedure was faster using the diode than erbium group laser, due to high absorption of diode wavelengths in melanin pigmentation[15].

After 1-2 weeks of laser therapy, re-epithelization is completed. At fourth week gingiva is similar to normal untreated gingiva but with absence of melanin pigmentation. The healing of laser wounds are slower than healing of scalpel wounds due to a sterile inflammatory reaction that occurs after laser use[16].

RADIOSURGERY

Radiosurgery is the most advanced form of electro surgery. It includes the removal of soft tissue with the aid of radio frequency energy.

Electrically generated thermal energy from the radiofrequency apparatus influences the molecular disintegration of melanin cells present on the basal and suprabasal layers of gingival epithelium. The latent heat of radiosurgery retards the development and migration of melanocytes making it more efficient compared to conventional methods.[17]

The pigmented areas are lightly touched with the electrode tip. Remove the electrode as soon as the tissue around the electrode becomes whitish. Repeat the procedure for all pigmented areas. After the first week, slight redness is observed around the margins of the surgical site. Epithelization is completed in 10 days and at 2 weeks post-op a second procedure can be performed in cases with heavy pigmentation.[18]

CRYOSURGERY TECHNIQUE

Robert Boyle reported almost 300 years ago the concept of cell destruction by freezing. The effect of cold temperature on living cells behaves like ionizing radiation, and the maximum lethal effect is obtained when they are applied to cells undergoing mitosis. Most vital tissues freeze at approximately -2°C, Ultra low temperature (below -20°C) results in total cell death[19].

a. Pre operative

b. Tissue blanching seen immediately after application of tetrafluoroethylene (TFE)

c. Post operative (after 3 months)
Pic Cortesy : Dent. J. 2020, 8, 88

Some of the cryogens commonly utilised for this procedure include the following. Cryogen effective temperature: Salt ice -20°C, CO2 slush -20°C, fluorocarbons (Freons)-30°C, nitrous oxide -75°C, CO2 snow-79°C, liquid nitrogen -20°C (Swab) -196°C (Spray), tetrafluoroethane (TFE) -20°C to -40°C.[20]

Following the procedure, at second to third day superficial necrosis becomes apparent and a whitish slough could be separated from the underlying tissue, that leaves a clean pink surface. In one to two weeks normal gingiva is formed. In 3-4 weeks, keratinization gets completed[21].

No postoperative pain, hemorrhage, infection or scarring is seen in these patients.

FREE GINGIVAL GRAFT

Free Gingival Grafts are used to create a widened zone of attached gingiva and in root coverage procedures.

The concept of using Free Gingival Graft for managing hyperpigmented gingiva was first described by Tamizi and Taheri[22] who replaced pigmented gingiva with unpigmented free gingival autografts in 10 patients. In their study, at least two areas were grafted; one with a full thickness flap and another with a partial thickness flap. They reported that there was no evidence of repigmentation for 4.5 years postoperatively in areas that received a full thickness flap, and only one instance of repigmentation was observed 1 year postoperatively in a patient treated with a partial thickness flap.

Although studies have shown favourable results, this technique required the use of additional surgical sites that add on to patients discomfort, and healing of the grafted sites was also reported to be slow and painful. Moreover, the satisfactory esthetic could not be achieved in most of the cases due to color differences between the palatal tissues and the gingiva[23].

Immediately after placement of the graft a fibrin clot forms between graft and the underlying tissue. Clot acts as a medium to transport nutrients from the recipient area to connective tissue of the graft. In the first week after surgery, re epithelization occurs with cells originating from lateral wound margins of epithelial ridges. By third day connective tissue proliferation begins and by the end of the first week a tenuous fibrous attachment between the graft and the recipient site is established. And by 14th day the epithelium presents a near normal histologic thickness[24].

ACELLULAR DERMAL MATRIX ALLOGRAFT (ADMA)

Acellular Dermal matrix Allograft are used mainly for treatment of soft tissue defects.[25] The acellular and non-immunogenic nature of this allograft promotes healing by repopulation and revascularization that favours to limit scarring.[26]

In a 12 month study, this method using ADMA for managing gingival melanin pigmentation was more efficient as compared to epithelium abrasion procedures[27]. The clinical studies demonstrated that ADMA has advantages of reduced surgical time (due to elimination of the surgical procedure for donor tissue), decreased post-operative complications, unlimited amount of graft material and a predictable and satisfactory esthetic result. However, it is expensive and requires clinical expertise.

CHEMICAL METHOD

In this treatment modality chemical agents are used to destroy the epidermis and/or dermis, aiding in depigmentation[28]. Chemical agents used are; phenols, salicylic acid, glycolic acid, trichloracetic acid, etc. These agents are classified into four types depending on their penetration: Very superficial, Superficial, Medium depth and Deep 90% phenol and 95% alcohol.

Phenol can penetrate the subepithelial connective tissue and cause necrosis or apoptosis of melanocytes. This result in reduced efficacy of melanocytes to normally synthesize melanin. Phenol never cause complete destruction, rather it only compromises melanocytic activity.

Chemical exfoliation is carried out by applying a phenol pellet and maintaining it for 1 minute in position. It can be repeated subsequently until satisfactory depigmentation is achieved. The area needs to be rinsed with 99% alcohol.

Ascorbic acid

Topical or parenteral application of Vitamin C (ascorbate, ascorbic acid) is one of the thera-

peutic approaches involved in skin depigmentation.

Melanin is one of the main reservoirs for Reactive Oxygen Species, copper and calcium. (Tsai et al., 2014). Once vitamin C is introduced to the target tissue, it binds efficiently to melanin due to its affinity to these reactive oxygen species (ROS), calcium and copper. This cause intracellular deficiency of these items and results in inability of the cells to produce melanin.

Vitamin C interacts with copper ions at the tyrosinase-active site and inhibits action of the enzyme tyrosinase, thereby decreasing the melanin formation. Vitamin C also acts on the perifollicular pigment.[29,30,31]

Gingival depigmentation using scalpel is so far the most widely practiced and convenient treatment approach. A recent systematic review also supports this fact, in which it was concluded that using scalpel have a good result in gingiva and scalpel is still a gold standard to treat gingiva hyperpigmentation[32]. Although it hurts, they cause minimal injury and gingival recurrence[33].

A major concern in the management of gingival hyperpigmentation is relapse or recurrence. It varies with each method. Patients must be educated regarding the possibility for the relapse following the procedure. They must be informed that repeated therapy for hyperpigmentation is quite normal and does not result in any adverse effects. It is advised that the clinicians should thoroughly educate their patients and must obtain an informed consent with special mention on gingival pigmentation recurrence from the patient prior to the procedure.

CONCLUSION

With the growing progress in esthetic dentistry, gingival depigmentation is nowadays becoming a common treatment procedure that is preferred by both the dentists as well as the patients. Various depigmentation techniques have been utilised for achieving the desired esthetics. However each method has its own advantages and disadvantages. Choosing the appropriate technique has often become a topic of debate. At the end all it matters is to provide optimum result that last for long and is of patient satisfaction.

REFERENCES

1. Garber D, Salama M. The aesthetic smile: diagnosis and treatment. Periodontal 2000 (1996); 11:18-28.
2. Goldzieher JW, Roberts IS, Rawls WB, et al. Chemical analysis of the intact skin by reflectance spectrophotometry. AMA Arch DermSyphilol 1951;64(5):533-48.
3. Color Range and Color Distribution of Healthy Human Gingiva: a Prospective Clinical Study.Ho DK, Ghinea R, Herrera LJ, Angelov N, Paravina RDSci Rep. 2015 Dec 22; 5():18498
4. Chatterjee A, Singh N, Malhotra P, Ajmera N. Gingival pigmentation and its treatment modalities. J Dent Scie Oral Rehab. 2011;2:11–4.
5. Anterior esthetic gingival depigmentation and crown lengthening: report of a case.Roshna T, Nandakumar K. J Contemp Dent Pract. 2005 Aug 15; 6(3):139-47
6. Doshi Y, Khandge N, Byakod G, Patil P. (2012): Management of gingival pigmentation with diode laser: is it a predictive tool; Int J Laser Dent, 2:29-32.
7. Baghani Z, Kadkhodazadeh M. Periodontal dressing: a review article. Journal of dental research, dental clinics, dental prospects. 2013; 7(4):183.
8. Murthy MB, Kaur J, Das R. Treatment of gingival hyperpigmentation with rotary abrasive, scalpel, and laser techniques: A case series. Journal of Indian Society of Periodontology. 2012; 16(4):614. 12.
9. Sameer AM. Management of gingival Hyperpigmentation by surgical abrasion: Report of three cases. Saudi Dent J 2006;18:162-6.
10. Shah R. Gingival depigmentation: case series for four different techniques. Nitte University Journal of Health Science, 2013.
11. Kaushik N, Srivastava N, Kaushik M, Gaurav V. Efficacy of different techniques of gingival depigmentation: a comparative evaluation with a case report. Int J Laser Dent. 2013; 3(2):68-72.
12. Hirschfeld I, Hirschfeld L. Oral pigmentation and a method of removing

it. Oral Surg Oral Med Oral Pathol1951;4:1012-6.

13. Willams D. Electrosurgery andwound healing: A review ofhelitera—ture. J Am Dent Assoc. 1984; 108(2):220-2.

14. Featured wavelength: Diode – The diode laser in dentistry (Academy report) wavelengths. Acad Laser Dent 2000;8:13.

15. I Cercadillo-Ibarguren, A. Espana-Tost, J. Arnabat-Dominguez, E. Valmaseda-Castellon, L. Berini-Aytes, C. Gay-Escoda. Histologic evaluation of thermal damage produced on soft tissue by Co2, Er, Cr: YSGG and Diode laser. Medicina Oral Patologia Oral y CirugiaBucal2010;15:912-18

16. Grover HS, Dadlani H, Bhardwaj A, Yadav A, Lal S. Evaluation of patient response and recurrence of pigmentation following gingival depigmentation using laser and scalpel technique: A clinical study. Journal of Indian Society of Periodontology. 2014; 18(5):586.

17. Sherman JA. Advances in radiosurgery. Inside Dentistry. Jul/Aug 2006:2-3.

18. Sherman JA, Gürkan A, Arikan F. Radiosurgery for gingival melanin depigmentation. Dentistry today. 2009; 28(1):118-20.

19. The histological reaction of clinically normal gingiva to freezing.Mayers PD, Tussing G, Wentz FM. J Periodontol. 1971 Jun; 42(6):346-52

20. Treatment of unsightly oral pigmentation: a case report.Bishop KDent Update. 1994 Jul-Aug; 21(6):236-7

21. Kumar S, Bhat GS, Bhat KM. Comparative evaluation of gingival depigmentation using tetra fluoro ethane cryosurgery and gingival abrasion technique: two years follow up. Journal of clinical and diagnostic research: JCDR. 2013; 7(2):389.

22. Tamizi M, Taheri M. Treatment of severe physiologic gingival pigmentation with free gingival autograft. Quintessence Int 1996;27:555-8.

23. Fowler EB, Breault LG, Galvin BG. Enhancing physiologic pigmentation utilizing a free gingival graft. Pract Periodontics Aesthet Dent 2000;12:193-6.

24. Campbell CM, Deas DE. Removal of an amalgam tattoo using a subepithelial connective tissue graft and laser deepithelialization. Journal of periodontology. 2009; 80(5):860-4.

25. Lattari V, Jones LM, Varcelotti JR, Latenser BA, Sherman HF, Barrette RR. The use of a permanent dermal allograft in full-thickness burns of the hand and foot: A report of three cases. J Burn Care Rehabil1997;18:147-55.

26. Tal H. Subgingival acellular dermal matrix allograft for the treatment of gingival recession: A case report. J Periodontol1999;70:1118-24.

27. Pontes AE, Pontes CC, Souza SL, Novaes AB Jr, Grisi MF, Taba M Jr. Evaluation of the efficacy of the acellular dermal matrix allograft with partial thickness flap in the elimination of gingival melanin pigmentation: A comparative clinical study with 12 months of follow-up. J EsthetRestorat Dent 2006;18:135-43.

28. Hirschfeld I, Hirschfeld L. Oral pigmentation and method of removing it. Oral Surg Oral Med Oral Path. 1951; 4:1012.

29. Matsuda S, Shibayama H, Hisama M, Ohtsuki M, Iwaki M. Inhibitory effects of novel ascorbic derivative VCP-IS-2Na on melanogenesis. Chem Pharm Bull 2008;56:292-7.

30. Draelos ZD. Skin lightening preparations and the hydroquinone controversy. Dermatol Ther2007;20:308-13.

31. Chang T. An update review of Tyrosinase inhibitors. Int J Mol Sci, 2009;10:2440-75

32. Haryo HM, Djais A, Adam A. The comparison of some depigmentation techniques towards reccurence of gingival hyperpigmentation: a systematic review. Makassar Dent J(2020);9:2

33. AlhabashnehR,et al. Gingiva depigmentation using Er:YAG laser and scalpel technique: A six - month prospective clinical study. Quintessence Int Periodontol 2018; 49(2).

IMPLANT SUPPORTED MANDIBULAR OVERDENTURE WITH OCCLUSAL MODIFICATION: A CLINICAL REPORT

Authors:

Dr. Ajay Mootha[1]
Dr. Kalyani Deshmukh[2]
Dr. Surojit Dutta[3]
Dr. Sushrut Bhagwat[4]

Professor and Head[1]
Department of Prosthodontics
Late Shri Yashwantrao Chavan Dental College
Ahmednagar 414001 Maharashtra

Post Graduate Student[2]
Department of Prosthodontics
Late Shri Yashwantrao Chavan Dental College
Ahmednagar 414001 Maharashtra

Assistant Professor[3]
Department of Prosthodontics
Late Shri Yashwantrao Chavan Dental College
Ahmednagar 414001 Maharashtra

Post Graduate Student[4]
Department of Prosthodontics
Late Shri Yashwantrao Chavan Dental College
Ahmednagar 414001 Maharashtra

Address for correspondence
Dr. Sushrut Bhagwat
Post Graduate Student
Department of Prosthodontics
Late Shri Yashwantrao Chavan Dental College
Ahmednagar 414001 Maharashtra
Email: sushrutb2@gmail.com

ABSTRACT

Implant-supported overdentures has become the treatment of choice for the completely edentulous mandible. They improve the quality of life in edentulous patients. Clinicians may select implant positions, number of implants based on the clinical scenario without affecting the quality of treatment. Conventional dentures are offered with acrylic resin denture teeth often exhibit rapid occlusal wear, which in turn decrease the chewing efficiency, loss of vertical dimension of occlusion, denture instability, temporomandibular joint disturbances, etc. There are various treatment modalities available like, use of highly cross linked acrylic teeth, amalgam or metal inserts on occlusal surface, use of composite, gold or metal occlusal surface, etc.

In this case report metal occlusion were included on the posterior teeth of acrylic teeth to overcome the drawbacks of the conventional denture mentioned above.

Keywords: Single mandibular denture, Implant supported overdenture, Metal occlusion.

J Ind Dent Assoc Kochi 2020;2(3):33-38.

INTRODUCTION

Preventive Prosthodontics emphasize the importance of any procedure that can eliminate or delay the future prosthodontic problems. Overdenture is defined as a removable partial denture or a complete denture that covers and rests on one or more remaining natural teeth, the roots of natural teeth, and/or dental implants.[1] Supported overdenture (teeth /implant) is a logical option to use in preventive Prosthodontics.

Implant-supported overdenture treatment is a popular and economical treatment modality with world-wide acceptance.[2] Approximately 60% of implant restorations in completely edentulous patients are restored with the implant-supported overdenture concept due to functional, anatomic, economical or esthetical considerations.[3] Implant-supported overdentures offer improved function, retention, stability proprioception and an acceptable level of comfort.[2,4,5]

MATERIALS & METHODOLOGY

A 46-year-old female patient reported to the Department of Prosthodontics, YCM & RDF's Dental College Ahmednagar complaining of missing teeth and with the expectation of improving chewing efficiency and appearance. The radiographic findings (Fig.1) revealed partially edentulous maxillary and mandibular arches and considerate amount of mandibular ridge resorption. No relevant medical related contraindications for implant surgery were found. The patient was proposed for the treatment plan of placing two-implants to support her lower overdenture and fixed metal full veneer prosthesis for posterior maxilla.

Fig 1: Pre-operative OPG

The treatment plan was accepted by the patient. Extraction in relation with 35,38,48 were done under local anaesthesia. Patient was assessed after 3 months for extraction healing (Fig.2a,2b). Diagnostic impressions and jaw relation was done. Casts were mounted and interridge distance was evaluated. At the surgical appointment, following the administration of local anesthetic, a mid-crestal incision was performed in anterior mandible and a full-thickness flap was reflected. Osteotomies were prepared followed by bone taps to countersink the sites, after which two implants of size 3.8mm x 11mm (myriad one-piece implants) were placed in B and D region .(Fig.3a)

The patient was given postoperative hygiene instructions, including the use of 0.12% chlorhexidine gluconate 3 times a day. She was furthermore prescribed 500 mg of amoxicillin (to be taken thrice daily for 5 days). After two days of post-surgery, she was called for a follow-up visit. Healing process was normal. After 3 months, the patient returned for another follow-up visit (Fig.3b). Osseointegration was verified using intraoral radiographs. Metal Fixed full veneer prosthesis (nickel chromium alloy)

Figure 2a: Maxillary arch

Figure 2b: Mandibular arch

Fig 3a:
Implant placement done in B and D region

Fig 3b:
Post-healing (after 3 months)

Fig.4: Rehabilitation of maxillary arch

was luted with GIC type I luting agent (GC gold label luting and lining) for 25, 26 27 and 16 for developing occlusion. (Fig.4)

Maxillary final impressions with alginate (ZHERMACK TROPICALGIN) and mandibular with heavy and light body polyvinyl siloxane (3M ESPE) were made (Fig.5a, b) and final casts were prepared. Jaw relation was recorded (Fig.6) along with facebow record and casts were mounted on semi-adjustable articulator. Teeth arrangement was done in balanced occlusion (Fig.7) and was verified during try-in in patients

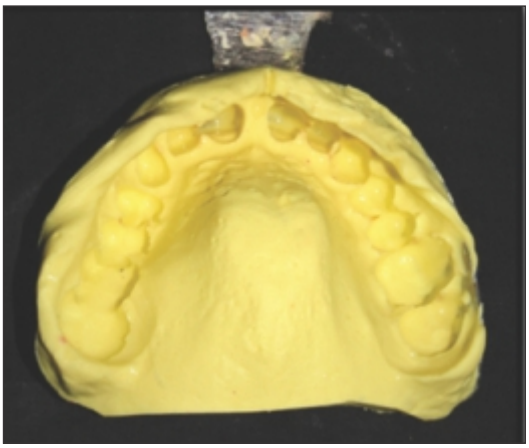

Fig.5a: Maxillary impression
Fig.5b: Mandibular impression

Fig.6: Jaw-relation recorded

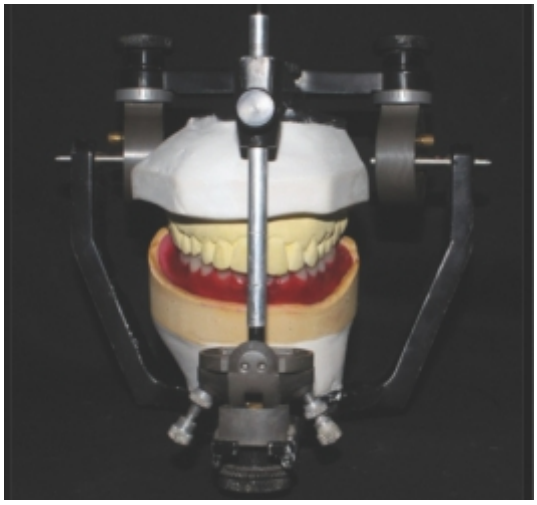

Fig.7: Teeth-arrangement on semi-adjustable articulator

Fig.8: Try-in done

mouth.(Fig.8). Metal meshwork was incorporated into the denture during processing.

Denture was remounted on the articulator. Sufficient interocclusal space was created by reducing mandibular posterior teeth (Fig.9a). The articulator was moved into lateral and protrusive positions to verify the space adequacy. The central portion of the teeth was reduced slightly more than the cusps to gain mechanical retention of the casting.

Then the inlay wax was added on the prepared denture teeth and the occlusal surface of the individual teeth was contoured (Fig.9b).

Fig.9a: Preparation of acrylic teeth done

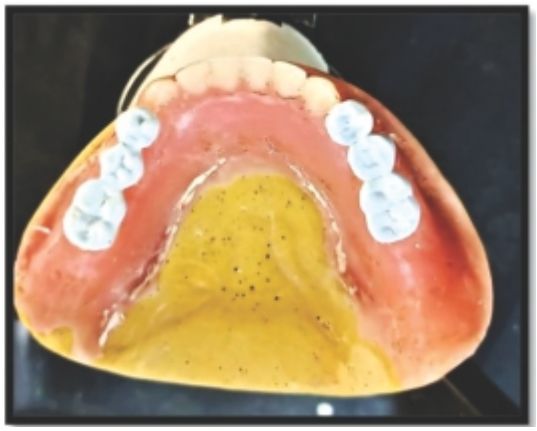

Fig.9b: Wax-pattern was fabricated

Secondary anatomic details were carved and the waxed occlusion was checked in centric, lateral and protrusive positions. Wax pattern was carefully removed from the teeth and casting was done with nickel chromium alloy followed by finishing and polishing.[6]

Polished castings were positioned at their respective sites on the denture teeth ensuring that each casting was completely cemented with resin cement (PANAVIA SA UNIVERSAL) (Fig.10a). Intaglio surface of denture had O-rings with metal housings (Fig.10b).

Fig.10a: Final denture with metal occlusion

Fig.10b: Intaglio surface of denture

The occlusion was checked in centric, lateral and protrusive positions (Fig.11a, b, c). Post insertion instructions were given and periodic follow up was done for 6 months, patient was further educated for proper maintenance of the implants and the prosthesis (Fig.12).

Fig.11a, b & c: Denture insertion centric , right centric, left centic

Fig.12: Post-operative photograph

DISCUSSION

According to JAMES H. DOUNDOULAKIS ET AL (2003) the implant-supported overdentures in the mandible provide good results with improved stability, retention, function and patient satisfaction compared to conventional dentures.[7] The long-term survival rate of the implants supporting overdenture is high. This percentage is comparable to other prospective studies that have reported survival rates of implants supporting an overdenture ranging from 86% to 100%.[8]

The number of implants needed for overdenture (two to four implants) is lesser than that required for a fixed implant prosthesis. This is an advantage because the volume of bone is reduced. Numerous long term studies have confirmed that implant supported overdentures provide satisfactory results with only two mandibular implants.[9,10] Further, it is generally accepted that for an edentulous mandible, two implant supported overdenture treatment is qualitatively standard of care rather than conventional denture treatment. Studies that compared and evaluated different types of attachment systems in terms of retention, ease of use, hygiene and stability, it was found that the number of implants and the type of attachment system did not significantly affect patient's acceptance and satisfaction with mandibular overdentures.[11,12] Many options are available for retention of the prosthesis, including magnets, clips, bars and balls.[13,14]

According to Rizwan Ali Shivji, Vaibhav D. Kamble, and Mohd. Atif Khan (2012) wear of the occlusal surface of the denture is a known fact which leads to subsequent changes in jaw relation, decrease in masticatory efficiency, loss of aesthetics, vertical dimension, aged looks. Use of wear resistant denture teeth that includes wear resistant resin or porcelain teeth, teeth with cast metal occlusal surface, and altering occlusal contact areas of denture teeth by use of silver amalgam fillings.[15]

Patient was reviewed every month for six months. Complications associated with this technique include postoperative bleeding, numbness if the mandibular nerve is disturbed during implant placement, infection and lack of osseointegration, debonding of metal occlusion and denture teeth, ridge resorption due to the excessive occlusal load created by metal occlusion. The risks can be minimized with proper training and experience.

CONCLUSION

The mandibular implant retained overdenture is proved to be successful and an economic treatment protocol. The literature indicates

that implant-supported overdentures in the mandible provide predictable results with improved retention, stability, patient satisfaction and function compared with conventional dentures. The clinical parameters such as masticatory efficiency, retention, stability and bite force needs to be investigated.

DECLARATION OF PATIENT CONSENT

The authors certify that they have obtained all appropriate patient consent forms. In the form, the patient has given her consent for her images and other clinical information to be reported in the journal.

REFERENCES

1. Academy of Prosthodontics, editor. The glossary of prosthodontic terms. Mosby; 1999.
2. Nissan J, Oz-Ari B, Gross O, Ghelfan O, Chaushu G. Long-term prosthetic aftercare of direct vs. indirect attachment incorporation techniques to mandibular implant-supported overdenture. Clinical oral implants research. 2011 Jun;22(6):627-30.
3. Sadowsky SJ. Mandibular implant-retained overdentures: a literature review. The Journal of prosthetic dentistry. 2001 Nov 1;86(5):468-73.
4. Al-Harbi FA. Mandibular implant-supported overdentures: Prosthetic overview. Saudi Journal of Medicine & Medical Sciences. 2018 Jan;6(1):2.
5. Muhammad AH, Abdulgani A, Bajali M, Giogrges C. The mandibular two-implant overdenture. Journal of Dental and Allied Sciences. 2014 Jan 1;3(1):58.
6. Kumar S, Arora A, Yadav R. An alternative treatment of occlusal wear: Cast metal occlusal surface. Indian Journal of Dental Research. 2012 Mar 1;23(2):279.
7. Doundoulakis JH, ECKERT SE, LINDQUIST CC, JEFFCOAT MK. The implant-supported overdenture as an alternative to the complete mandibular denture. The Journal of the American Dental Association. 2003 Nov 1;134(11):1455-8.
8. Timmerman R, Stoker GT, Wismeijer D, Oosterveld P, Vermeeren JI, Van Waas MA. An eight-year follow-up to a randomized clinical trial of participant satisfaction with three types of mandibular implant-retained overdentures. Journal of dental research. 2004 Aug;83(8):630-3.
9. Fontijn-Tekampl EA, Slagter AP, Van't Hof MA, Geertman ME, Kalk W. Bite forces with mandibular implant-retained overdentures. Journal of dental research. 1998 Oct;77(10):1832-9.
10. Stoker GT, Wismeijer D, Van Waas MA. An eight-year follow-up to a randomized clinical trial of aftercare and cost-analysis with three types of mandibular implant-retained overdentures. Journal of dental research. 2007 Mar;86(3):276-80.
11. Geertman ME, Slagter AP, Van Waas MA, Kalk W. Comminution of food with mandibular implant-retained overdentures. Journal of Dental Research. 1994 Dec;73(12):1858-64.
12. Stellingsma K, Slagter AP, Stegenga B, Raghoebar GM, Meijer HJ. Masticatory function in patients with an extremely resorbed mandible restored with mandibular implant-retained overdentures: comparison of three types of treatment protocols. Journal of Oral Rehabilitation. 2005 Jun;32(6):403-10.
13. Trakas T, Michalakis K, Kang K, Hirayama H. Attachment systems for implant retained overdentures: a literature review. Implant dentistry. 2006 Mar 1;15(1):24-34.
14. Stellingsma K, Slagter AP, Stegenga B, Raghoebar GM, Meijer HJ. Masticatory function in patients with an extremely resorbed mandible restored with mandibular implant-retained overdentures: comparison of three types of treatment protocols. Journal of Oral Rehabilitation. 2005 Jun;32(6):403-10.
15. Shivji RA, Kamble VD, Khan M. Custom Metal Occlusal Surface for Acrylic Resin Denture Teeth to Enhance Wear Resistance: A Case Report. Case reports in dentistry. 2012;2012.

A CASE OF EXPANSILE INTRAOSSEOUS LESION OF POSTERIOR MAXILLA IN 11 YEAR OLD GIRL

Authors:

Dr. Bhavna Barthunia[1]

Dr.Poulomi Bhakta[2]

Professor and Head[1]
Department of Oral Medicine and Radiology
Daswani Dental College and Research Centre
Kota, Rajasthan

Senior Lecturer[2]
Department of Oral Medicine and Radiology
Daswani Dental College and Research Centre
Kota, Rajasthan

Address for correspondence
Dr. Bhavna Barthunia
Talwandi,
Kota, Rajasthan
E mail: bhavnashell@rediffmail.com

ABSTRACT

Neoplastic and non neoplastic lesions of the jaws are classified as radiopaque or radiolucent, odontogenic or non-odontogenic. Certain pathologies are radiolucent, radiopaque or mixed. The purpose of this article is to provide a better understanding of imaging of the lesion based on literature review and demonstrated by clinical findings & radiographic findings. Many lesions that occur in the jaw have a similar radiographical appearance and it is often difficult to differentiate among them. Use of CBCT along with clinical finding helps in narrowing the differential diagnosis.

Keywords: jaw lesion, maxillary lesion, CBCT.

J Ind Dent Assoc Kochi 2020;2(3):39-42.

INTRODUCTION

A 11-year-old girl complained of a painless swelling involving the left midfacial region. History revealed presence of the swelling since 8 months, which was initially groundnut size and gradually increased in size. Medical history was non contributory. She was not on any medication. On clinical examination, a mixed dentition was found. Intraoral swelling of 3.5 cm x 2.5 cm diameter was noted involving the left buccal vestibule, gingival tissues in relation to 24,65,26 region. Buccal expansion was more prominent as compared to palatal expansion. The lesion was covered by normal-appearing mucosa. Lesion was nontender firm in consistency with no discharge from it. [Figure 1]. There were no other growth or swelling elsewhere in the body.

Clinical differential diagnosis given were

1. Dentigerous cyst in relation to 25
2. Ameloblastoma
3. Monoostotic fibrous dysplasia
4. Juvenile ossifying fibroma
5. Calcifying epithelial odontogenic tumor
6. Odontogenic myxoma

INTRA ORAL VIEW

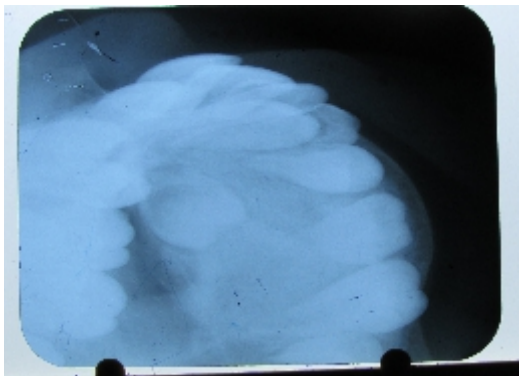

MAXILLARY OCCLUSAL VIEW

Orthopantomograph (OPG) showed well defined mixed (radiolucent & radiopaque) lesion in the left posterior maxillary area extends from the forming root of 24 distally to the distal region of 26. [Figure 2]. Maxillary lateral occlusal view revealed a round with irregular centrally placed radiopaque areas surrounded with radiolucent halo, causing buccal and palatal cortical plate expansion. Developing 25 has been displaced mesially, positioned above the root of 24 [Figure 3]. Axial view [Figure 4A] & Sagittal view [Figure 4B] of CBCT revealed a massive well defined, mixed (hypodense and hyperdense) expansile lesion with regular margins seen in the buccal alveo-

OPG VIEW

AXIAL VIEW OF CBCT

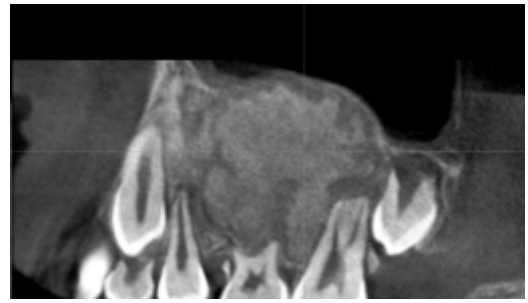

SAGGITAL VIEW OF CBCT

lar crest region in relation to teeth 24,65,26 region. The lesion was approximately round with irregular centrally placed hyperdense areas surrounded with halo of hypodensity, causing buccal and palatal cortical plate expansion. Mesiodistal dimension was 35.8mm, buccopalatal dimension was 27.2mm and superoinferiorly it measured 28.4mm.

The radiographic differential diagnosis were given as calcifying epithelial odontogenic tumour, adenomatoid odontogenic tumour, monostotic fibrous dysplasia and juvenile ossifying fibroma.

The patient was referred to Dept. of Oral and Maxillofacial surgery for further investigation & treatment.

DISCUSSION

The literature reports that intraosseous tumour usually manifests as a painless swelling that causes slow bone expansion.[1-4] The lesion usually consists of a radiolucent area, which may be well or poorly defined, uni or multilocular, containing radiopaque masses of varying size and opacity. In several cases, especially in tumours of relatively short duration, the calcification is very small and may be undetectable on radiographs. When an unerupted tooth is associated with the tumour, the radiopacities tend to be located close to tooth crown.[1,3] Fibrous dysplasia is usually found in young adults, as seen in our case of a 11 year old female patient.[5] The radiographic appearance of FD depends on the stage of development and amount of bony and fibrous matrix within the lesion.[6] Early lesions appear radiolucent, and mature lesions may appear sclerotic.[7] The different radiographic patterns on the basis of radiodensity are ground glass appearance, orange peel appearance, cottonwool appearance, amorphous dense and fingerprint pattern.[8] The most common radiographic appearance is ground glass opacification which results from superimposition of numerous poorly-calcified bony trabeculae arranged in a unsystematic pattern as in present case.[6]

AOT usually is asymptomatic and identified mainly in the second decade of life, with half of the cases occurring in teenage years, and there is a slight predilection for the female gender.[9,10]

Ossifying fibroma (OF) usually is not associated with pain, and some cases are detected as incidental findings during routine radiographs.[11] Conventional OF usually occurs in the second and fourth decades of life, with a reported predilection for the female gender.[12]

CONCLUSION

Jaw lesions are difficult to distinguish from each other on radiography. The patient's history and an analytical approach to radiographs help in narrowing down the differential diagnosis.The recent advent of cone-beam computed tomography (CBCT) can enhance the quality of the diagnosis and preoperative assessment of such lesions.

REFERENCES

1. Philipsen HP, Reichart PA. Calcifying epithelial odontogenic tumour: biological profile based on 181 cases from the literature. Oral Oncology 2000;36:17-26.
2. Kaplan I, Buchner A, Calderon S, Kaffe I. Radiological and clinical features of calcifying epithelial odontogenic tumour. Dentomaxillofac Radiol 2001;30:22-28.
3. Houston GD, Fowler CB. Extraosseous calcifying epithelial odontogenic tumor: report of two cases and review of the literature. Oral Surg Oral Med Oral Pathol Oral Radiol Endod 1997;83:577-583.
4. Cheng YSL, Wright JM, Walstad WR, Finn MD. Calcifying epithelial odontogenic tumor showing microscopic features of potential malignant behavior. Oral Surg Oral Med Oral Pathol Oral Radiol Endod 2002;93:287-295.
5. Eliana Dantas da Costa, Priscila Dias Peyneau, Francielle Silvestre Verner, Solange Maria de Almeida, Glaucia Maria Bovi Ambrosano. Monostotic fibrous dysplasia: a case report with cone-beam computed tomography findings. RGO - Revista Gaúcha de Odontologia, 2017;65(2):180-184
6. Ava Nikbin, Seiedeh Tahereh Mohtavipour, Alieh Sadat Javadzadeh Haghighat, Saeed

Dhjashtyari,Mohammad Talebzadeh.Craniofacial Fibrous Dysplasia: New Image Findings Journal of Dentomaxillofacial Radiology, Pathology and Surgery Winter 2017;5(4):23-26.

7. Kenniyan Kumar Srichinthu, Thukanayakanpalayam Ragunathan Yoithapprabhunath, Ravi Teja Chitturi, Andamuthu Yamunadevi, Aparna Devi Potsangbam, Deepak Ningombam Singh. Fibro Osseous Lesions – Classifications, Pathophysiology and Importance of Radiology: a Short Review Int. Biol. Biomed. J. Winter 2016;2(1)11-20

8. Stuart C White, Michael J Pharoah. Oral Radiology Principles and Interpretation. 6TH edition. Page no. 428- 432.

9. Curran AE, Miller EJ, Murrah VA. Adenomatoid odontogenic tumor presenting as periapical disease. Oral Surg Oral Med Oral Pathol Oral Radiol Endod. 1997;84(5):557-60. https://doi.org/10.1016/S1079-2104(97)90273-0

10. Philipsen HP, Srisuwan T, Reichart PA. Adenomatoid odontogenic tumor mimicking a periapical (radicular) cyst: a case report. Oral Surg Oral Med Oral Pathol Oral Radiol Endod. 2002;94(2):246-8. https://doi.org/10.1067/moe.2002.124767

11. MacDonald DS. Maxillofacial fibro-osseous lesions. Clin Radiol. 2015;70(1):25-36.

12. Barnes L, Eveson JW, Reichart P, Sidransky D, editors. Pathology and genetics of head and neck tumours. Lyon: IARC; 2005. (World HealthOrganization Classification of tumours).

ESTHETIC REHABILITATION OF MIDLINE DIASTEMA - A CASE SERIES

Authors:

Dr. Lydia Almeida[1]
Dr. Adi Deepika Mani[2]
Dr. Jayasheela M[3]
Dr. Triveni M G[4]

Post Graduate Student[1]
Department of Periodontics
Bapuji Dental College and Hospital
Davangere, Karnataka

Post Graduate Student[2]
Department of Periodontics
Bapuji Dental College and Hospital
Davangere, Karnataka

Professor[3]
Department of Periodontics
Bapuji Dental College and Hospital
Davangere, Karnataka

Professor and Head[4]
Department of Periodontics
Bapuji Dental College and Hospital
Davangere, Karnataka

Address for correspondence
Dr. Lydia Almeida
Post Graduate Student
Department of Periodontics
Bapuji Dental College and Hospital
Davangere, Karnataka
E mail: lydiaalmeida0@rediffmail.com

ABSTRACT

Teeth plays a major role when ones confidence is concerned and periodontist is at-most important in balancing the white and pink ratio. Combined role of Periodontists and esthetic dentist played a major role in managing the white pink ratio in the present case series. The authors present three cases in which high frenal attachment was taken care along with unequal gingival margin and diastema closure. This article concludes that frenectomy, crown lengthening and veneering can be used to restore tooth form and esthetics.

Key words: High frenal attachment, Frenectomy, Diastema, Veneers.

J Ind Dent Assoc Kochi 2020;2(3):43-46.

INTRODUCTION

The shape size and colour of the gums and teeth play an important role when esthetics is considered. Feeling of happiness, love, kindness and courtesy are better expressed through the simple act of smiling.[1] Thus it is no surprise that we encounter more frequently individuals reporting to the dental office seeking an ideal smile.[2] Midline diastema caused due to an aberrant frenum raises esthetic concerns.[3] Similar esthetic concerns are dealt with individuals having a gummy smile with excessive gingival display.[1]Mosby's Dental Dictionary defines esthetic dentistry as, "the skills and techniques used to improve the art and symmetry of the teeth and face to enhance the appearance as well as the function of the teeth, oral cavity, and face."Any dentist who wants to become an esthetic dental practitioner needs to learn and apply his/her artistic skills simultaneously with technical knowledge.[4] A well done naturally looking restoration too will fall short to meet the esthetic demands of the patients if the gingival contour is not in harmony with it. Thus when a patient is to be treated with the aim to fulfill his/her esthetic demand a correctly done treatment planning with a multidisciplinary approach is a must.[5]

Here we describe 3 cases which were done by the mutual coordination between the Periodontics and the endodontist to carry out procedures like frenectomy, crown lengthening and veneering which would bring out a more harmonious smile and enhance function.

Case Report 1

A 26 year old Male patient reported with a chief complaint of discolored teeth in upper anterior region. On intraoral examination there was a high frenal attachment present in relation to 11 and 21 (gingival type), the tension test was positive and frenectomy was decided as the choice of treatment followed by crown lengthening for 21.

The patient was evaluated and found to be systemically healthy and his verbal and written consent was taken and phase I therapy was carried out with satisfactory maintenance. For the surgery, the area was anaesthetized and Chu's aesthetic gauge was used as a guide to establish a correct dimension of clinical crowns (figure1). External bevel incision was given using 15c blade. The frenectomy was carried with the conventional technique.[2] Sutures were placed using 4-0 silk sutures. Postoperative instructions were given to the patient and analgesics were prescribed whenever required. The

1a. Pre Operative measurement

1b. Gingivectomy incision

1c. Conventional frenectomy

1d. Post treatment

patient was recalled after 1 week for suture removal and kept under maintenance and veneers were planned accordingly.

Case report 2

A female patient aged 29 years reported with the chief complaint of spacing in 11 and 21region. On intra oral examination, the patient had midline diastema with high frenal attachment (papillary type) and tension test was positive (figure 2). The conventional type of frenectomy was planned and the case was managed as described above.

Case report 3

A 30 year old female patient presented with the chief complaint of spacing between 11 and 21. On Intraoral examination there was a presence of high frenal attachment (papilla penetrating type) and tension test was positive and V-Y type of frenectomy was planned. (figure 3)

2a. Pre Operative

2b. Frenectomy

2a. Suturing

2b. Post-treatment results

3a. Pre Operative

3b. Incision

3c. V Incision given

3d. Frenum tissue reloaded

3e. Fost treatment results

DISCUSSION

A frenum is a fold of mucous membrane, usually with enclosed muscle fibers, that attaches the lips and cheeks to the alveolar mucosa or gingiva and underlying periosteum, An aberrant frenum can cause periodontal pocket formation, gingival recession and midline diastema.[6] Frenectomy is a procedure where complete excision of the frenum along with it attached fibers were removed. It can be performed by various techniques like V- plasty, V-Y pasty, Z-plasty or the classical technique described by Archer.[2] The selection of technique is based on the type of the frenal attachment which is classified by Placek et al (1974) as mucosal, gingival, papillary and papillary penetrating type. Not only the recent advances like electro-surgery and Laser minimize the complications and fasten the wound healing, but also the traditional method maintains its gold standard in its management.[7] The presented case series achieved proper relocation of the frenum with stable outcome.

Waal and Castellucci explained the importance of the periodontal biological width around the tooth. It is calculated to be around 2.04mm.[8] In our cases also excessive gingival display was seen which was managed through gingivectomy using Chu's gauge. Chu's aesthetic gauges are series of gauges that help to methodologically approach aesthetic crown lengthening procedure. Moreover the procedures like crown lengthening enables us to fabricate restorations like veneers to improve function and keep the integrity of the surrounding hard and soft tissues. This also ensures that the restorative margins do not violate the biological width.[9] Veneers which are used to correct discoloured teeth, abnormal tooth forms, and minor tooth malpositioning have long stood the test of time in patients unwilling for prolonged and complex orthodontic treatment.[10] Complete diastema closure was achieved in our cases and the patients were well satisfied with the treatment.

Hence this article concludes that frenectomy, crown lengthening and veneering can be used to restore tooth form and esthetics. Meticulous treatment planning helps in achieving the pink and white esthetic form.

REFERENCES

1. Srivastava R, Verma P K, Chaturvedi T P, Srivastava A, Yadav P. Miracle of perio-plastic surgery: Treatment for esthetic smile. SRM Journal of Research in Dental Sciences. 2013 Jul 1;4(3):125.
2. Devishree SK, Shubhashini PV. Frenectomy: a review with the reports of surgical techniques. Journal of clinical and diagnostic research: JCDR. 2012 Nov;6(9):1587.
3. Huang WJ, Creath CJ. The midline diastema: a review on its etiology and treatment. Pediatric Dentistry 1995;17:171-9.
4. Goldstein RE. Esthetic dentisty- a health service. Journal of Dental Research 1993:3:641–642.
5. Zucchelli G, Sharma P, Mounssif I. Esthetics in periodontics and implantology. Periodontology 2000. 2018 Jun;77(1):7-18.10.
6. Desai AJ, Bedi S, Gowda TM, Thomas R, Mehta DS. Bilateral pedicle approach for esthetic management of upper labial frenum. Journal of Interdisciplinary Dentistry. 2015 Jan 1;5(1):27.
7. Morosolli AR, Veeck EB, Niccoli-Filho W, Gomes MF, Maria das Graças VG. Healing process after surgical treatment with scalpel, electrocautery and laser radiation: histomorphologic and histomorphometric analysis. Lasers in medical science. 2010 Jan 1;25(1):93.
8. De Waal H, Castellucci G. The importance of restorative margin placement to the biologic width and periodontal health. Part II. Int J Periodontics Restorative Dent 1994;14:70-83.
9. Nautiyal A, Gujjari S, Kumar V. Aesthetic Crown Lengthening Using Chu Aesthetic Gauges And Evaluation of Biologic Width Healing. Journal of Clinical and Diagnostic Research: Jcdr. 2016 Jan;10(1):ZC51.
10. Alothman Y, Bamasoud MS. The success of dental veneers according to preparation design and material type. Open Access Macedonian Journal of Medical Sciences. 2018 Dec 20;6(12):2402.

MICROSCOPES IN DENTISTRY - OPEN THE THIRD EYE

Authors:

Dr. George Jacob

Conservative Dentist
and Endodontist,
All For Roots
Edappally, Kochi, Kerala

Address for correspondence
Dr. George Jacob
Conservative Dentist
and Endodontist,
All For Roots
Edappally, Kochi, Kerala
E mail: allforroots@gmail.com

ABSTRACT

Operating Microscopes have changed the way we practice Endodontics and other finer specialties of Dentistry. Magnification and Illumination has become the basic necessity in a day to day Dental Practice. In this article along with a brief history of magnification in Dentistry, the various advantages of incorporating operating microscope are discussed in a detail.

Key words: Operating microscopes, endodontics, magnification.

J Ind Dent Assoc Kochi 2020;2(3):47-50.

INTRODUCTION

Science is advancing in a fast pace, so is the practice of dentistry. What makes dentistry different now is the incorporation of newer gadgets and concepts, out of which magnification takes a prime role in helping the clinicians, see what we never saw before with our naked eyes. This article sums up the advantages what operating microscopes offer to Clinicians and why we should be incorporating it in our day to day practice.

HISTORY

It was in 1673 that Anton Van Leevenhock, a Dutch scientist first saw and explained the red blood cells under microscope[1]. He was a self-taught man in science, with his single lensed microscopes explored the wonders of human body and introduced the science of medicine to a new field of microbiology. Later in the late 19th century, Carl Nylen, a Swedish Otologist used a monocular microscope for ear surgery in 1921. Gunner Holmgren developed a binocular microscope for microsurgeries in 1922[2]. Microscopes were introduced in Dentistry by Dr. Harvey Apotheker and Dr. G.J. Jako in 1978 and published in 1981[3]. The use of microscopes in Endodontics was explained first by Carr in 1992.[4]

ADVANTAGES OF USING A DENTAL OPERATING MICROSCOPE (DOM)

1. Seeing is Believing

Many cases can be better diagnosed and many procedures can be better done when we have an improved vision and magnification. Certain conditions like cracked tooth syndrome are better diagnosed with a DOM which we fail to pick up with other diagnostic aids

A crack extending from the mesial aspect of premolar is better seen and explained under a microscope which explains the shooting pain for this patient. Radiographs may not help in such cases.

2. Less fatigue to the eyes and better ergonomics

The eyepiece of the DOM works with the principle of telescope. That helps the operator to see his images at a distance which renders less fatigue to the eyes. Dental surgeons are highly prone for occupational disorders related to bad posture. DOM helps you to maintain the correct relaxing unstrained position for your spine and neck.

3. Better Documentation and communication

A high definition camera can be attached to the microscope which can record the videos and photographs of your procedures. This allows you to communicate better with your patients and referring dentists and also use these for your academic purpose and research.

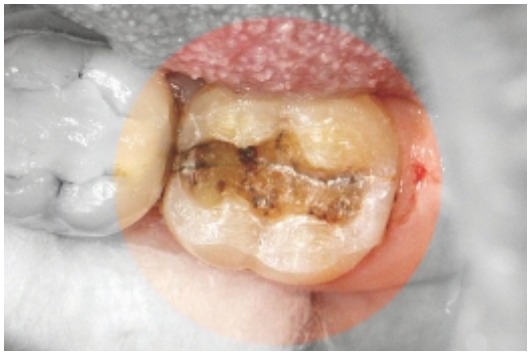

A crack running under an old amalgam restoration was better diagnosed and explained to the patient with the help of a microscope.

4. Better surgical precision

The precision of surgery increases with magnification. Flaps are more accurately repositioned. Sutures are better positioned. Vital Pulp procedures are better managed.

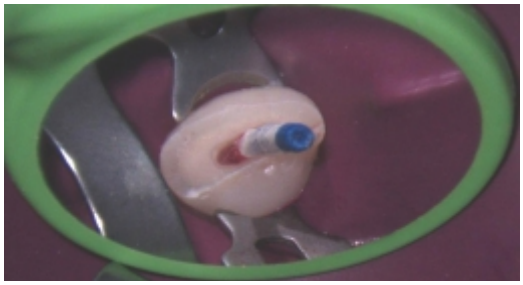

Following an Ellis Class III traumatic injury to a central incisor, the coronal pulp is removed and bleeding arrested using a sterile paper point. Surgical precision is enhanced under microscope.

5. Improved treatment quality and patient satisfaction

With magnification, the precision what you attain leads you to better treatment quality and better patient communication with improved patient satisfaction.

6. Endodontic retreatment and management of complications

Management of post treatment endodontic disease has always been a challenge in specialty practice. DOM open a new dimension in managing these challenges related to calcified canals, open apex, ledges, perforation repair, removal of root canal obturating material and the management of separated instruments.

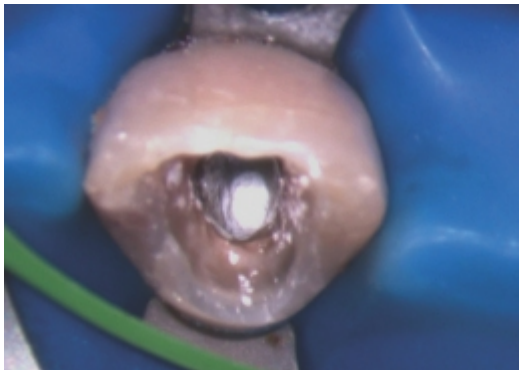

MTA packed at the root apex of a tooth with open apex.

7. Locating the fine and additional canals in Endodontics

Anatomical diversity has always been a challenge in Endodontics. The presence of canals at unexpected locations can be better seen and managed under magnification. The second mesiobuccal canals of a maxillary molar, the middle mesial canal of a mandibular molar are certain examples.

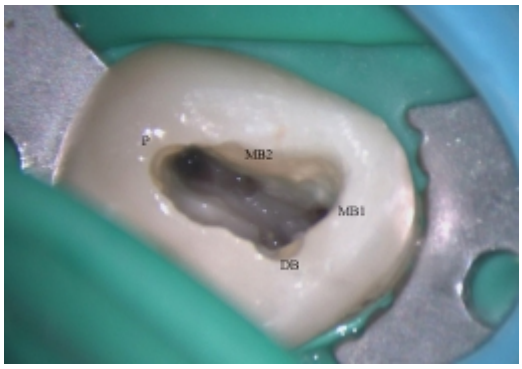

Second Mesiobuccal canal of a maxillary second molar is better managed under a microscope

8. Better margins for prosthetic work

Marginal Integrity is the foremost requirement for the durability of any restoration. Good margins ensure healthy gingiva and less plaque accumulation around margins. It is important when we go in for fine procedures like crowns, laminates, inlays and onlays. Preparation, Impression and Bonding under microscopes ensure better marginal integrity.

Working under a DOM is an entirely different ball game. You need expertise, training and at the same time an open mind to incorporate the concepts of micro-dentistry. Good assistance with six handed dentistry and a good practice management is the key to have a successful microscopic practice.

REFERENCES

1. A historical note on cell theory. Dominico Ribatti, J. of Experimental Cell Research. Volume 364, Issue 1, 1 March 2018, Pages 1-4.
2. The history of the microscope for use in ear surgery. A Mudry. Am J Otol 2000 Nov;21(6):877-86.
3. A microscope for use in dentistry. Apotheker H, Jako GJ. J Microsurg. 1981; 3: 7-10.
4. Microscopes in endodontics. Carr GB. J Calif Dent Assoc 1992;20:55-61.

JIDAK

JOURNAL OF INDIAN DENTAL ASSOCIATION - KOCHI

frequency 9495696209